

Automatic White Matter Lesion Segmentation in FLAIR MRI

Sai Prasanth.S¹, Shinu Rajan Mathew², Mobin Varghese Mathew³ & Rahul.B.R⁴

UG Student, Department of ECE, Rajas Engineering College, Vadakkangulam, India,¹

UG Student, Department of ECE, Rajas Engineering College, Vadakkangulam, India,²

UG Student, Department of ECE, Rajas Engineering College, Vadakkangulam, India³

UG Student, Department of ECE, Rajas Engineering College, Vadakkangulam, India⁴

ABSTRACT: Abnormal changes in the white matter, known as white matter lesions (WML). WMLs are related to stroke and carotid disease. To reduce the long-term disabilities associated with stroke, accurate volume measurements are most important. In general, it is difficult for medical experts to accurately quantify the WMLs due to decreased contrast between White Matter and Grey Matter. The aim of this project is to automatically segment the White Matter Lesions which is present in the brain MRI. In this project, a generalized multiple-kernel fuzzy C-means (MKFCM) methodology is introduced as a framework for image-segmentation problems. The proposed MKFCM algorithm provides us a new flexible vehicle to fuse different pixel information in image-segmentation problems. Lesion load studies are included that automatically analyze WML volumes for each brain hemisphere separately. Simulations are performed on the FLAIR MRI medical images to demonstrate the flexibility and advantages of MKFCM-based approaches.

KEYWORDS: white matter lesion, multiple kernel fuzzy c mean, lesion load, fluid attenuation inversion recovery.

I. INTRODUCTION

Medical imaging is the technique used to create images of the human body for clinical or medical science that produce images of the internal aspect of the body. Magnetic Resonance Imaging (MRI) is one of the medical imaging techniques. MRI of brain is highly sensitive for detecting all forms of White Matter abnormalities. Non-specific changes in the White Matter appear frequently on MRI in elderly patients presenting with either stroke or cognitive impairment. In general, human brain consists of main components namely, White Matter (WM), Grey Matter (GM). Neuronal tissue containing mainly long, myelinated axons is known as White Matter. Closely packed neuron cell bodies form the Grey Matter. Grey Matter is in grey color because of the grey nuclei that comprises the cells. Myelin is responsible for the white appearance of White Matter. White Matter Lesions (WMLs) are commonly found in patients with Multiple Sclerosis (MS), Cerebrovascular Disease (CVD), stroke, and other neurological disorders. It is believed that the total volume of the lesions and their progression relate to the aging process as well as disease process. Therefore, quantification of White Matter Lesions is very important in understanding the aging process and diagnosis and assessment of these diseases.

II. RELATED WORKS

Anbeek *et al.* [1] proposed *k*-nearest neighbors algorithm (*k*-NN) for automatic segmentation of WMLs. This is a supervised learning method and used the information from T1-weighted, inversion recovery (IR), proton density-weighted (PD), T2-weighted, and fluid attenuation IR (FLAIR) scans in order to estimate the probability of voxels. T1-weighted scans are a standard basic scan, in particular differentiating fat from water - with water darker and fat brighter. This is one of the basic types of MR contrast and is a commonly run clinical scan. T2 - weighted scans are another basic type. Like the T1-weighted scan, fat is differentiated from water. but in this case fat shows darker, and

water lighter. For example, in the case of cerebral and spinal study, the CSF (cerebrospinal fluid) will be lighter in T2-weighted images. By combining the results of these techniques, binary segmentation results are obtained from the selected threshold values, and therefore the relation between an optimal threshold and lesion volume was separately chosen for each patient.

A probability mixture model and the Bayesian classifier was used by Khayati *et al.* [2] in order to extract normal tissue, abnormal tissue and cerebrospinal fluid (CSF) which serves primary purpose like buoyancy, protection and chemical stability. Normal tissue refers to White Matter and Grey Matter of brain whereas abnormal tissue refers to lesions of brain in FLAIR-MR images. This method does not focus on the lesions of small size or irregular shape.

Lao *et al.* [3] proposed an approach for segmenting WML in which support-vector machine (SVM) classifier was used in order to classify new scans, and post processing analysis was carried out to eliminate false positives. The strength of SVM-based classifiers is the ability to separate overlapping features, but selecting effective features for classifying a particular difficult problem is one of the key issues in pattern classification that should be first identified, where the results are based on only expert-defined information. This method is less accurate. Therefore WML image intensities cannot be visually distinguished.

III. METHODOLOGY

This paper mainly focuses on automated segmentation of White Matter Lesions of brain using fast and efficient clustering algorithms. The goal of clustering a medical image is to simplify the representation of an image into a meaningful image and makes it easier to analyze. However clustering techniques are sensitive to initialization and are easily trapped in local optima.

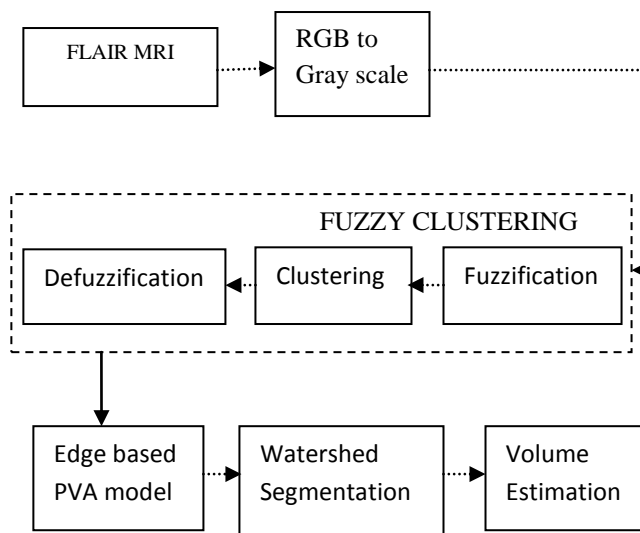


Fig.1. Block diagram representation

A. Multiple kernel fuzzy c mean clustering

The proposed multiple kernel fuzzy c-means (MKFC) algorithm which extends the fuzzy c-means algorithm with a multiple kernel learning setting. By incorporating multiple kernels and automatically adjusting the kernel weights, MKFC is more immune to ineffective kernels and irrelevant features. This makes the choice of kernels less crucial. The kernel FCM (KFCM) algorithm is an extension of FCM, which maps the original inputs into a much higher dimensional Hilbert space by some transform function. After this reproduction in the kernel Hilbert space, the data are

more easily to be separated or clustered. Multiple-kernel methods provide us a great tool to fuse information from different sources. The application of multiple or composite kernels in the FKCM has its advantages. In addition to the flexibility in selecting kernel functions, it also offers a new approach to combine different information from multiple heterogeneous or homogeneous sources in the kernel space. The input data involve properties of image pixels sometimes derived from very different sources. Therefore, we can define different kernel functions purposely for the intensity information and the texture information separately, and we then combine these kernel functions and apply the composite kernel in MKFCM to obtain better image-segmentation results.

STEPS:

- Initializing a random membership matrix satisfying non-negative and unity constraints.
- Optimal weights are calculated using $\omega_k = \frac{1}{\frac{1}{\beta_1} + \frac{1}{\beta_2} + \dots + \frac{1}{\beta_M}}$ by fixing the memberships where β_k is coefficient.
- Optimal memberships are updated using $u_{ic} = \frac{1}{\sum_{c=1}^C \left(\frac{D_{ic}^2}{D_{ic}^2} \right)^{\frac{1}{m-1}}}$ where D_{ic} is the distance between input data and cluster center..
- The process is repeated until the amount of change per iteration in the membership matrix falls below a given threshold.

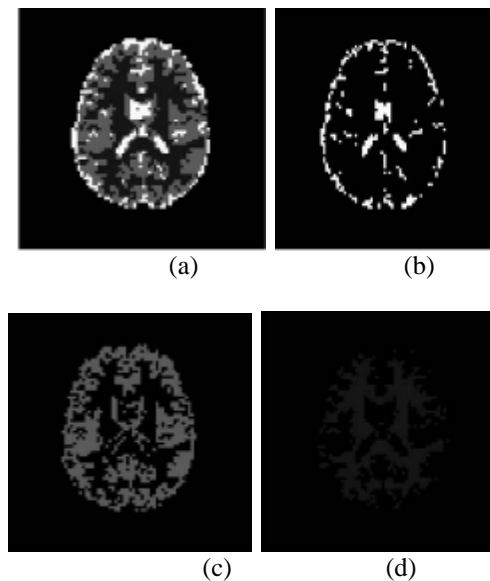


Fig. 2. Clustering of an MR image. (a) MR image (b)WM (c)GM (d)CSF

B. Edge-Based PVA Modeling

Edge detection refer to the process of identifying and locating sharp discontinuities in an image. The discontinuities are abrupt changes in pixel intensity which characterize boundaries of objects in an image. PVA occurs over specific intensity ranges, and moreover, with high edge values. To compute this metric, the traditional magnitude of the gradient, i.e., g , is first estimated by,

$$g = \|\nabla y\| = \sqrt{\left| \frac{\partial y}{\partial x_1} \right|^2 + \left| \frac{\partial y}{\partial x_2} \right|^2} \quad (1)$$

The gradient magnitude of the primary segmentation is obtained by applying the Sobel operator.

C. Watershed Transform

Watershed transform is a segmentation method in mathematics morphology. In geography, a watershed is the ridge that divides areas drained by different river system. The watershed transform is a morphological gradient-based segmentation technique. The gradient map of the image is considered as a relief map in which different gradient values correspond to different heights. If we continue pouring water, the water level will rise over the catchment basins (CB). When two different body of water meet, a dam is built between them. The progress continues until all the points in the map are immersed. Finally the whole image is segmented by the dams which are then called watersheds and the segmented regions are referred to as catchment basins (CB). A catchment basin (CB) is the geographical area draining into a river or reservoir. The watershed algorithm applies these ideas to gray-scale image processing in a way that can be used to solve a variety of image segmentation problem.

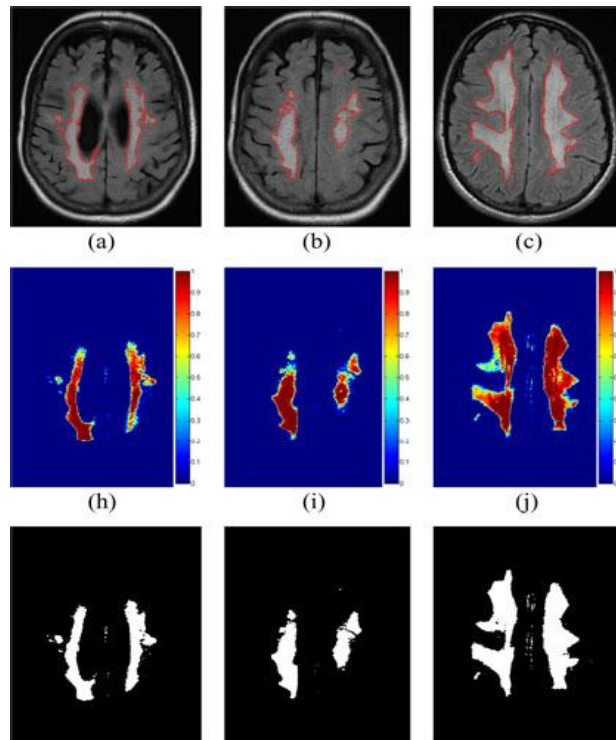


Fig.3.segmentation of FLAIR MRI

III. VOLUME ESTIMATION

As WMLs are related to stroke and carotid disease, accurate volume measurements are most important. Manual volume computation is laborious, subjective, time consuming, and error prone. Automated methods are a nice alternative since they quantify WML volumes in an objective, efficient, and reliable manner. The volumes of the lesions are computed with

$$V = \left(\sum_i \xi_{WML}^T(x_i) \right) \times \frac{w \times h \times d}{100} \text{ mL} \quad (2)$$

Where $w \times h \times d$ is the dimensions of each voxel in mm^3 and ξ_{WML}^T is the thresholded WML class membership map.

On 4th September, 2015

Organized by

Department of CSE, ECE & EEE, Magna College of Engineering, Chennai-600055, India.

IV. LL STUDIES

LL was an important marker for the study of WML's relationship to stroke. In particular, the correlation between LL in one hemisphere of the brain and a ruptured plaque in the carotid artery on same side of the body (ipsilateral) was quantified. To get the LLs for each hemisphere; an extra processing step is used to locate the centerline dividing the two hemispheres. A simple algorithm based on the center of mass is used and an example result is displayed in Fig.2.6, which contains the detected midline and the corresponding left and right WML segmentations.

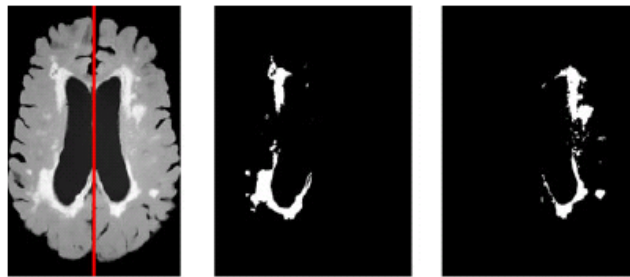

Fig.4. Detection of Hemispheres and segmented lesions.

As carotid disease has been linked to ischemic stroke, the nature of the relationship between WML and carotid disease is being heavily researched to learn more about the pathogenesis of stroke. To objectively represent the difference in the WML volume between brain hemispheres, a metric called the hemispheric WML volume difference or ΔLL is defined as,

$$\Delta LL = \frac{|LL_L - LL_R|}{LL_L + LL_R} \quad (3)$$

where LL_L is the LL of the left hemisphere, and LL_R is the LL for the right. This is a normalized metric that measures the hemispheric LL in reference to the total LL of the patient. It is maximum when there are no lesions in one hemisphere while the other hemisphere is WML positive.

V. CONCLUSION

As WMLs are related to stroke and carotid disease, accurate volume measurements are most important. Manual volume computation is laborious, subjective, time consuming, and error prone. Automated methods are a nice alternative since they quantify WML volumes in an objective, efficient, and reliable manner. The first process uses MKFCM clustering to produce a primary segmentation. Then PVA is modeled with a localized edge strength measure since PVA resides in the boundaries between tissues. LL studies can be used to measure the volume of the WML in the left and right hemispheres of the brain separately, which has the potential to advance medical research on stroke and carotid disease. If the value of ΔLL is large, the disease is more progressive and advanced in one of the hemispheres. As WML have been shown to be related to carotid disease ipsilaterally, large differences in the hemispheric LLs could be an indication of advanced carotid disease.

REFERENCES

- [1] Anbeek,P, K. Vincken, M. van Osch, R. Bisschops, and J. van der Grond,(2004), "Probabilistic segmentation of white matter lesions in MR imaging," *NeuroImage*, vol. 21, no. 3, pp. 1037-44.
- [2] Khayatia.R, M. Vafadusta, F. Towhidkhaha, and S.M. Nabavib,(2008), "Fully automatic segmentation of multiple sclerosis lesions in brain MR flair images using adaptive mixtures method and Markov random field model," *Comput. Biol. Med.*, vol. 38, no. 3, pp. 379-390.
- [3] Lao.Z, D. Shen, A. Jawad, B. Karacali, D. Liu, E. Melhem, R. Bryan, and C. Davatzikos, (2006), "Automated segmentation of white matter lesions in 3D brain MRI, using multivariate pattern classification," in *Proc. IEEE Int.Symp. Biomed. Imaging (ISBI)*,pp. 307-310.
- [4] Boer R. de, H. A. Vrooman, F. van der Lijn,M.W. Vernooij, M. A. Ikram, A. van der Lugt, M. M. Breteler, and W. J. Niessen,(2009), "White matter lesion extension to automatic brain tissue segmentation on MRI," *Neuroimage*, vol. 45, no. 4, pp. 1151-1161.
- [5] Yanga.F, Z.Y. Shanb, and F. Kruggela,(2010), "White matter lesion segmentation based on feature joint occurrence probability and χ^2 random field theory from magnetic resonance (MR) images," *Pattern Recognit. Lett.*, vol. 31, no. 9, pp. 781-790.