

Observation of Histopathological Changes in Tracheal Tissue of Larvae of Dragonfly *Diplocodes Trivialis* under the Stress of Textile Dyeing Effluent

D.Chitra , A.Reniprabha , G.Dhanalakshmi , and K.Sivakumar

PG and Research, Department of Zoology. Chikkaiah Naciker College, Erode. TamilNadu, India

ABSTRACT: The present study showed the effect of different concentrations of textile dyeing effluent on tracheal tissue of dragonfly larvae. Bioassay tests were carried out by using the larval instar of dragonfly *D.trivialis* and textile dyeing effluent collected from textile industries. The LC 50 / 96 hr value of the effluent to the larvae was found to be 30%. In control larvae, the trachea has normal epithelial cells and it is closely associated with haemopoietic tissue. In effluent treated larvae ,the epithelial changes in trachea was obvious and there was anaplastic sarcomatous type of carcinoma infiltrating in between the muscle bundles with necrosis , thus proving the toxicity of textile dye effluent after chronic exposure.

KEY WORDS: Histopathology, Textile dyeing effluent ,*Diplocodes trivialis*

I. INTRODUCTION

The respiratory physiology of aquatic insects is governed by several factors including their tolerance to pollutants.Among the industrial effluents the textile dyeing effluent is found to be more toxic to aquatic organisms under various toxicity tests. Most of its studies on textile dyeing effluent have contributed to the effect of these pollutants on fishes and other vertebrates and not much work has been done in invertebrates in particular to odonates. Histopathology is used to study the impact of toxic materials as it provides the real picture of the toxic effects of xenobiotics in vital functions of a living organism [1]. Although aquatic insects like assess water quality , their respiratory strategies have received little attention .Hence , histopathological changes due to the textile dyeing effluent stress in the dragonfly larvae *Diplocodes trivialis* has been investigated in the present study.

II. MATERIALS AND METHOD

The dragonfly larvae were collected from their natural breeding places and the textile dyeing effluent was collected from local dyeing industry. The static bio assays were carried out to find out Lc 50/96 hrs value of the effluent to the larvae and it was found to be 30 % .In the sub lethal concentrations of the effluent, the larvae exhibited no moulting and died on day 35 .The experimentation was , therefore , carried on day 10 , 20 , and 30 which corresponded to the inter moult stages of the last three larval instars. From the control and effluent – treated larvae the tracheal tissues were dissected out and processed by following the method of [2] with slight modifications. The material was fixed immediately in 10 % formol saline for 2 hrs, dehydrated in graded alcohol, cleared in xylene and embedded in paraffin wax. The sections of 5 μ thickness were stained with hematoxylin using eosin as counter strain and microphotographed.

International Journal of Innovative Research in Science, Engineering and Technology

(An ISO 3297: 2007 Certified Organization)

Vol. 4, Issue 9, September 2015

III. RESULT AND DISCUSSION

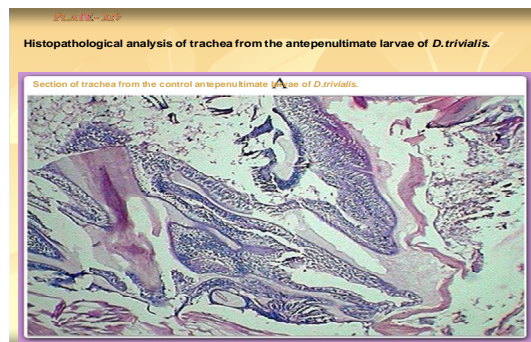
The tracheal tissue is well associated with the haemopoietic tissue and, it was very difficult to separate tracheal from the haemopoietic tissue. The plate 1. clearly illustrated the histological details of tracheal tissue.

In the present experimental larvae there were no changes in the tracheal histology at lower concentrations (1%) and at early exposure period (10 days) whereas in 2% effluent treated larvae, focal dysplastic changes in the epithelium of tracheal tissue was followed by formation of cancer cells with the dysplastic epithelium in 3% effluent exposed larvae (plate.2).

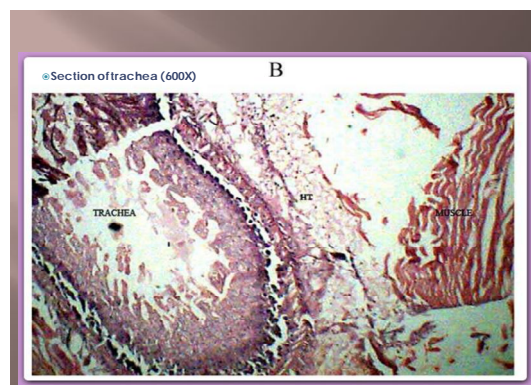
The effect of effluent on 20 days exposure was portrayed in plates 3. At lower concentrations (1% and 2%) hyperplastic changes were observed in tracheal mucosa of treated larvae. There was anaplastic carcinoma, infiltrating the muscle bundles in 3% effluent toxicity. After 30 days of exposure, there was anaplastic sarcomatous type of carcinoma infiltrating in between the muscle bundles and necrosis in tracheal mucosa cells was observed in treated tracheal tissue (plate.4)

Due to pollutant stress, the smooth living of tracheal surfaces gets disrupted as reported by [3,4] have also observed lifting of outer layer of lamellar epithelium and hyperplasia of respiratory tissue under Cu toxicity. Evidence of dysplasia and poorly differentiated cells reveal an indication of malignancy. Almost malignant changes was seen in tracheal tissue which corroborates the observation of [5]. This extensive tissue damage of the trachea indicating impairment of respiratory functions, which would increase oxygen demand [6]. Hence the textile dyeing effluent – induced tracheal tissue damage resulted in mortality of larvae.

Histopathological analysis of trachea from the antepenultimate larvae of *D.trivialis*. (plate -1)



Section of trachea from the control antepenultimate larvae of *Diplocodes trivialis* (600X) (plate-2)

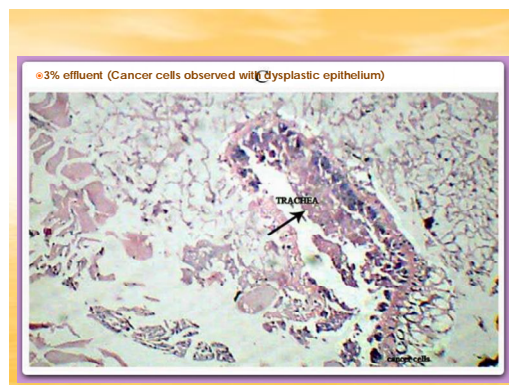


International Journal of Innovative Research in Science, Engineering and Technology

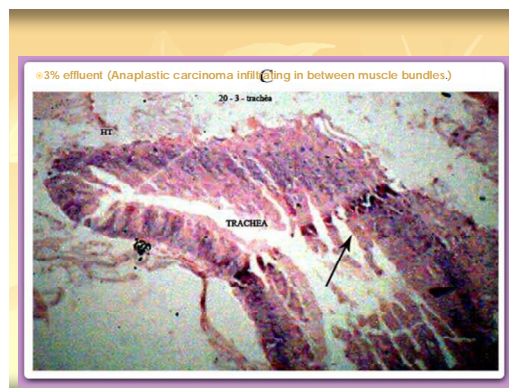(An ISO 3297: 2007 Certified Organization)

Vol. 4, Issue 9, September 2015

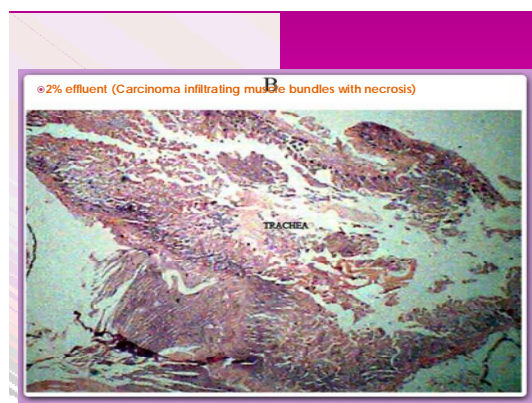© Plate -2. Section of trachea from the larvae treated in 3% effluent (Cancer cells observed with dysplastic epithelium) 10 days of exposure.



Histopathological analysis of trachea in TDE-treated larvae of *D.trivialis* after 20 days of exposure.



2% effluent (Carcinoma infiltrating muscle bundles with necrosis)



International Journal of Innovative Research in Science, Engineering and Technology

(An ISO 3297: 2007 Certified Organization)

Vol. 4, Issue 9, September 2015

REFERENCES

- [1].Ramalingam , Effects of DDT and Malathion on tissue succinic dehydro generate activity and lactic dehydrogenase isoenzymes of Sarotherodon mossambicus, Proc ,Indian .Acad ,Sci ,(Anim,sci),94(5),527. 1985
- [2].Weesner ,F.M. General zoological microtechniques, Williams and Wilkins company ,Baltimore ,Indian Edition ,Scientific Book Agency ,Calcutta. 1968.
- [3].Anjalismita,SunitaDutta and Abhijitdudf .Effect of $Cuso_4$ an the respiratory tissue of dragonfly nymph (Anisoptera)at variable ferpenticule .The Biscan 5(3):517-521.2010.
- [4].Martinez ,C.B.R,Nagal ,M.V.Zaia , T.B.V and Zaia ,D.A.M.Acute morphological and physiological effects trends in netropical fish , Prochilodus lineatus Bron 2.J.Biol.,64 (4):797-807.2004
- [5].Umbuzeiro ,G.A. The contribution of azo dyes to the mutagenic activity of the cristais River ,Chemosphere,60 ;55-64. 2005.
- [6].Timshy ,M.R.Blackstone ,B.J.Nixdrof and Tayler ,H.D.Exposure of lead induces hypoxia –like response in bullfrog larvae (Rana catesbioeiana).Env.Toxicol,and Chem.18(10):2283-2288.1999.