

# **Remote Automated Cataract Detection System Based on Fundus Images**

Sucheta Kolhe<sup>1</sup>, Shanthi K. Guru<sup>2</sup>

P.G. Student, Department of Computer Engg, D.Y. Patil College of Engineering, Pune, Maharashtra, India<sup>1</sup>

Assistant Professor, Department of Computer Engg, D.Y. Patil College of Engineering, Pune, Maharashtra, India<sup>2</sup>

**ABSTRACT:** Cataract is an eye disease which is responsible for vision loss and blindness. In this paper, remote automated cataract detection system is proposed to detect the cataract efficiently and to help patients to know their cataract condition timely, so that they can get proper treatment from doctors. The remote cataract detection system is deployed on the cloud, so clients can access system remotely. This system mainly consists of four stages namely preprocessing, feature extraction, classification and grading. Binary SVM is implemented to classify the fundus image and for grading, MDA algorithm is applied. Classification is carried out for two classes i.e. non-cataract and cataract. Grading part consists of three classes i.e. mild, moderate and severe cataract. The dataset used is real-world dataset containing 261 images. SVM algorithm provides better results than MDA algorithm used for classification.

**KEYWORDS:** Cataract, fundus images, image processing, classification, retina, grading

## **I. INTRODUCTION**

Cataract is clouding of the lens in the eye which is painless and developed gradually over a long period. Cataract is an eye disorder which occurs when some of protein at lens clumped together that makes it dull and increases opacity of the lens, causing some loss of vision. On the basis of area where cataract develops, cataract is classified into three types namely, nuclear cataract, cortical cataract and posterior sub-capsular cataract. Nuclear cataract develops deep in the nucleus of lens. It is associated with aging. Cortical cataract occurs in the lens cortex, which is the part of the lens that surrounds the central nucleus. Posterior sub-capsular cataract occurs at the back of the lens. People with diabetes or those taking high doses of steroid medications have a greater risk of developing this type of cataract.

Cataract is the leading cause of visual impairment in the world today and is responsible for up to 50% of blindness globally [1]. From the report of WHO in 2004, it is cleared that there are 53.8 million people in world suffering moderate to severe disability caused by cataract, 52.2 million of whom are in low and middle income countries [1].

The retina is the light-sensitive tissue at the back of the eye which is responsible for changing light into nerve signals that are sent to the brain. The fig.1 shows the fundus images of non-cataract and mild, moderate and severe cataract image respectively. As shown in fig. 1, the non-cataract image provides more details regarding blood vessels, optic disc and macula. Blood vessels (even the capillary) are clearly shown in non-cataract image but as the severity of cataract increases, clarity of blood vessels and optic disc is decreased. Mild cataract image provides less information about the blood vessels. Moderate cataract image shows only trunk vessels, so it provides little information about the blood vessels and optic disc. There is hardly anything in the severe cataract one's.

Automated cataract classification system mainly consists of three steps: preprocessing, feature extraction and classification. In preprocessing step, the RGB image is converted into green channel image and by applying image processing techniques, the contrast is enhanced and noise is removed. Then from the resultant image, features of retina are extracted by means of various operators and algorithms. Based on extracted features, classification step is carried out. For classification, supervised and unsupervised learning algorithms are used. After that, grading step comes. Clinically, ophthalmologists evaluated the degree of cataract by comparing the picture observed through camera with a

# International Journal of Innovative Research in Science, Engineering and Technology

(An ISO 3297: 2007 Certified Organization)

Vol. 5, Issue 6, June 2016

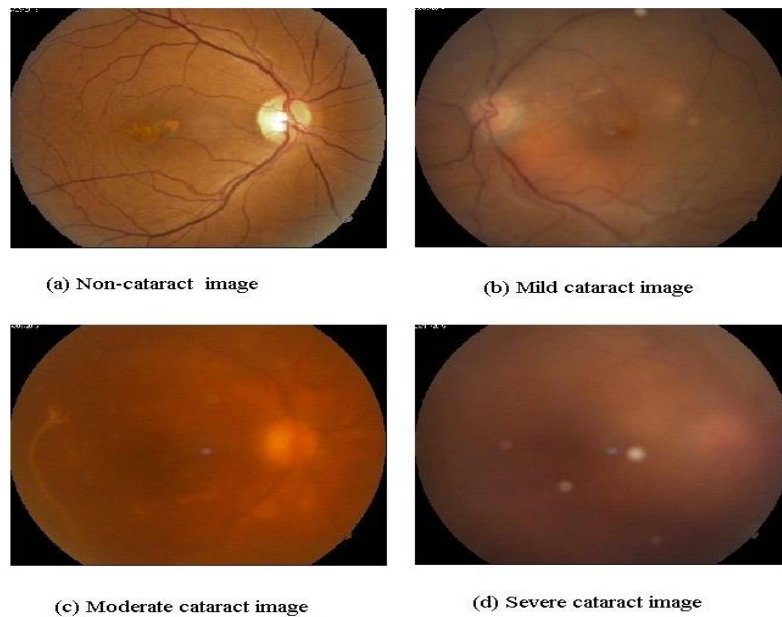


Fig.1 Fundus images of non-cataract and cataract in different gradings i.e. mild, moderate and severe cataract

series of standard photographs, which is termed as clinical grading. The clinical grading is quite subjective. In order to improve the grading objectivity, human graders are trained to classify cataracts based on photographs or digital images, which is termed as grader's grading. Grading process takes five to ten minutes to grade an image. The experience of ophthalmologist also plays vital role in grading. So there is need to develop an efficient cataract detection system which will help to reduce the burden of ophthalmologists and will provide the status of cataract to the patient timely, efficiently and remotely.

Paper is organized as follows. Section II describes different techniques used by researchers to detect the opacity of the cataract. The flow diagram represents the step of the algorithm. Architecture and overview of proposed system is given in Section III. Section IV provides details about algorithms used. Section V presents experimental results showing results of images tested. Finally, Section VI presents conclusion.

## II. RELATED WORK

In [2], S. Fan et al. developed an automatic system for classification of nuclear sclerosis from slit-lamp photographs. Authors detected the visual axis and extracted important feature landmarks. Linear regression was used to select features and linear grading function using those features was fit using the Standards. Then they graded the severity of nuclear sclerosis based on the intensities of those landmarks. The system achieved accuracy of 95.8%.

H. Li et al. developed an automatic grading system for nuclear cataract assessment [3]. To detect the lens contour from the slit-lamp images, bottom-up and top-down strategies were combined. Bottom-up strategy included lens localization using horizontal and vertical intensity profile clustering and Ellipse estimation of Lens. Top-down strategy used a modified ASM to detect contour of lens. The mean intensity inside the detected lens contour was used to indicate the opacity of the nuclear cataract. Authors showed that the difference between automatic grading and clinical grading is acceptable.

H. Li et al. implemented a computer-aided system to assess nuclear cataract automatically using slit-lamp images [4]. An enhanced Active Shape Model (ASM) was applied to extract robust lens contour from slit-lamp images. A Support

# International Journal of Innovative Research in Science, Engineering and Technology

(An ISO 3297: 2007 Certified Organization)

Vol. 5, Issue 6, June 2016

Vector Machine (SVM) scheme was used to grade nuclear cataract automatically. This study showed that 97.8% of automatic grades are within one grade difference to human grader [4].

In [5], H. Li et al. developed an algorithm to detect cortical opacities from retro-illumination images, and to grade the severity of cortical cataract objectively. The combination of canny edge detection, Laplacian approach and convex hull approach was applied to detect the edge pixels. The detected pixels were further fitted to an ellipse by non-linear least square fitting. In order to detect cortical opacity specifically, the spoke feature was used to separate from other opacities such as PSC [5]. The detection results of local thresholding and edge detection in each direction were merged. H. Li et al. developed an automatic system for PSC opacity detection in retro-illumination images [6]. The pupil detection was based on the edge detection and ellipse fitting. The features detected were intensity, edge, size and spatial location. The sensitivity and specificity were 82.6% and 80% respectively [6].

Chow, Yew Chung, et al. presented a new approach for automatic detection based on texture and intensity analysis to address the problems of existing methods [5, 6] (over-detection and under-detection) and improve the performance from three aspects, namely ROI detection, lens mask generation and opacity detection [7]. Image clipping was applied first to remove the bright spots in the retro-illumination image. Then the texture analysis was done to classify the image into two categories i.e. clear lens and lens with moderate or severe opacity. For clear lens, only texture filtering was applied to obtain the final result. While for non-clear lens, both global thresholding and texture analysis using local entropy were used to detect the opacity [7].

Gao, Xinting, et al. presented the enhanced texture feature based on the grader's expertise of cataract and the characteristics of the retro-illumination lens images [8]. The statistics (such as mean, standard deviation, skewness and kurtosis) of the enhanced texture feature was used to train the linear discriminant analysis to detect the cataract. The accuracy of 84.8% was achieved.

Xu, Yanwu, et al. presented a system to automatically grade the severity of nuclear cataracts from slit-lamp images. The system consists of three components: ROI and structure detection, feature extraction, and prediction [6]. The authors proposed a regression based framework with BOF group features and a group sparsity constraint for joint feature selection, parameter selection and regression model training [9].

Ruchir Srivastava et al. presented automatic grading of nuclear cataract (NC) from slit-lamp images using image gradients [10]. The system mainly consists of three steps namely, preprocessing, feature extraction and grade prediction. First, the lens region was localized automatically using horizontal and vertical profile clustering and then structure was detected using a modified version of active shape model (ASM). Features related to gradient aspects (such as Location, orientation, and magnitude) were extracted. These features are used in combination with prior features related to color and brightness.

In [11], Liye Guo et al. presented a computer aided system for automatic classification and grading of cataract on the basis of fundus image analysis. The system was built up with three main stages: preprocessing of image, feature extraction, cataract classification and grading. Image features were extracted by means of wavelet transform (Haar transform) and sketch based method in combination with discrete cosine transform. Multiclass discriminant analysis was used to classify the images into cataract and non-cataract images and then graded into mild, moderate and severe cataract. The correct classification rate for hybrid of wavelet transform and sketch based method classification and grading was 89.3% and 73.8% respectively [11].

Researchers are trying to develop the automated diagnosis system for retina related diseases such as diabetic retinopathy [12] age-related macular degeneration [13], glaucoma [14]. The retinal features such as retinal lesions [15], optic disc [16], fovea [17], blood vessels [18] are detected by automated systems proposed by the researchers.

### III. SYSTEM ARCHITECTURE

The proposed system comprises preprocessing, feature extraction, classification and grading stages. Fig. 2 shows the system architecture of the proposed system. Firstly the input image is taken from the fundus image dataset, then image is preprocessed using Contrast-limited Adaptive Histogram Equalization (CLAHE). Features are extracted to classify the image accurately. For feature extraction two methods are used. First is Discrete Wavelet Transform (DWT) and another is skeletonization with Discrete Cosine Transform (DCT). This method gives coefficients of DWT and DCT. Principle Component Analysis (PCA) is applied on these coefficients. Based on extracted features, SVM algorithm is

applied for classification of image into two classes i.e. cataract and non-cataract image. For grading, MDA algorithm is used. If the image is classified as cataract image then and then only the grading is applied on classified image. If the image is classified into non-cataract class, then grading step is not performed. This cataract detection system is deployed on Amazon AWS cloud from which the user or patient can get the result of their disease. For this, patient or ophthalmologist has to upload the image first on cloud. By using cloud, the patients or ophthalmologists located in different area can also access the system and can get the status of their cataract developed in their eye.

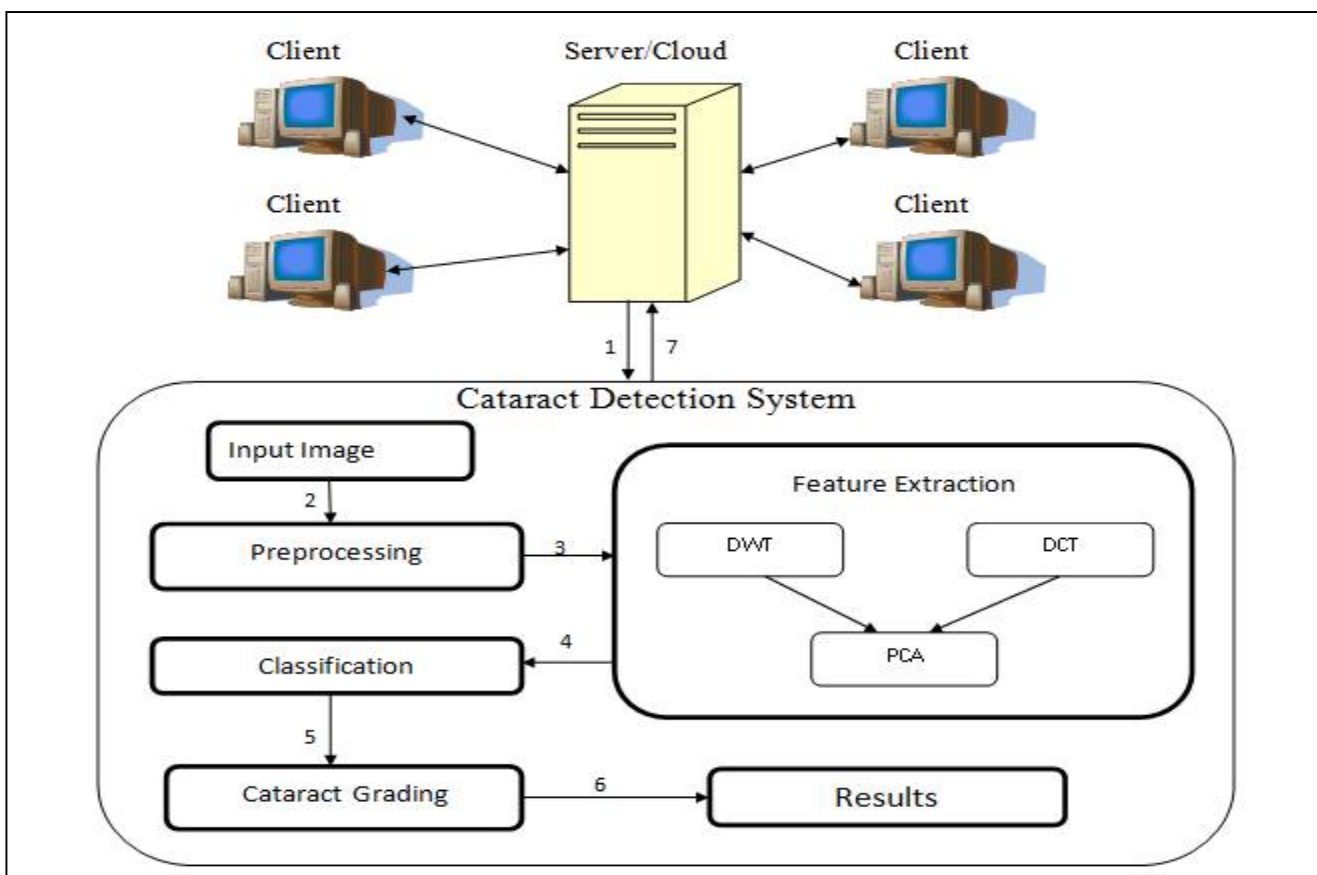


Fig.2 Architecture of Proposed System

The architecture of the proposed system contains different modules explained as follows:

1. **Testing Dataset:-** A real-world dataset is divided into training and testing dataset. The testing dataset consists of cataract and non-cataract fundus images of various patients. These images are labeled by the experienced ophthalmologist.
2. **Preprocessing:-** Histogram equalization is used to uniformly adjust the contrast of the image. Preprocessed image is obtained by mapping each pixel with level  $r_k$  in the input image into a corresponding pixel with level  $S_k$  in the preprocessed image via following equation.
 
$$S_k = T(r_k) = \sum_{j=0}^k \Pr(r_j)$$
3. **Feature Extraction :-** The localized features related to the high frequency components, such as the details related to edges or sudden small peaks are considered as features. These features are usually hard to be recognized in space domain but easily discovered in frequency domain. According to this consideration, DWT and DCT techniques are used to calculate the high frequency components of image. Before applying DCT, skeletonization is performed to reduce foreground regions in a binary image to a skeletal remainder that

largely preserves the extent and connectivity of the original region. Then using Principal Component Analysis (PCA), the dimensions are reduced and appropriate features are selected for classification.

4. **Training Dataset:-** The past fundus images are used as a training dataset. Binary SVM algorithm is used to train and test the images with the help of this training dataset.
5. **Classification using SVM algorithm:-** SVM (Support Vector Machine) is used to classify the input fundus image. Linear kernel is used to implement the SVM algorithm which helps to classify the image into non-cataract and cataract class. To detect cataract, the past fundus images from training dataset are used as an input for SVM.
6. **Grading using MDA:-** Multi-class fisher discriminant analysis algorithm (MDA) is implemented to grade the cataract image into mild, moderate and severe classes.

## IV. ALGORITHMS

1. **Discrete Wavelet Transform:-** Discrete Wavelet Transform (DWT) is used for extracting high frequency components in the fundus image. For this, Haar wavelet transform is used. Haar transform contains terms such as addition, subtraction and division by two. Thus, no multiplications are needed because most elements of the Haar wavelet transform matrix are zero.

The pseudocode for algorithm1 is as follows:-

1. Treat the array as  $n/2$  pairs called (a, b).
2. Calculate  $(a + b) / \sqrt{2}$  for each pair, these values will be the first half of the output array.
3. Calculate  $(a - b) / \sqrt{2}$  for each pair, these values will be the second half.
4. Repeat the process on the first half of the array. (The array length should be a power of two)

2. **Multi-class Fisher Discriminant Analysis:-** Algorithm 2 details multi-class fisher discriminant algorithm for grading. The basic idea of linear discriminant analysis is to find a linear transformation that best discriminate among classes and the classification is then performed in the transformed space based on some metric such as Euclidean distance. In multi-Fisher discriminant, projection is from a  $D$ -dimensional space to a  $K-1$  dimensional space. For  $K$ -class problem, Fisher Discriminant Analysis involves  $(K - 1)$  discriminant functions. Here, two notions are used i.e.  $S_W$  and  $S_B$  where,  $S_W$  is the within-class covariance matrix of  $K$  classes,  $S_B$  is the between-class covariance matrix of  $K$  classes.  $W$  is called a weight vector.

The pseudocode for algorithm2 is as follows:-

**Input :** X, Y, Nc

**Output :** P (Projection matrix  $P \in \mathbb{R}^{(p \times d)}$ )

1. Compute mean vector for each class:  $m_c = \frac{\sum_{i=1}^{N_c} x_i}{N_c}$
  2. Compute total mean vector:  $m = \frac{\sum_{i=1}^N x_i}{N}$
  3. Compute within-class scatter:  $S_B = \sum_{c=1}^C \sum_{j=1}^{N_c} (x_j - m_c)(x_j - m_c)^T$
  4. Compute between-class scatter:  $S_W = \sum_{c=1}^C N_c(m_c - m)(m_c - m)^T$
  5. Eigen decomposition:  $[V;D] = \text{eig}(S_B/S_W)$
  6. Get the projection matrix.
3. **Support Vector Machine:-** SVM is a machine learning algorithm for binary classification. Let  $(x_1, y_1) \dots (x_n, y_n)$  be the set of  $n$  training examples, where each instance  $x_i$  is a vector in  $\mathbb{R}^N$  and  $y_i(-1, +1)$  is the class label. In their basic form, a SVM learns a linear hyperplane that separates the set of positive examples from the set of negative examples with maximal margin (the margin is defined as the distance of the hyperplane to the nearest of the positive and negative examples). The linear separator is defined by two elements: a weight vector  $w$  (with one component for each feature), and a bias  $b$  which stands for the distance of the hyperplane to the origin. The classification rule of a SVM is:

$$\text{sgn}(f(x, w, b)) \quad (1)$$

# International Journal of Innovative Research in Science, Engineering and Technology

(An ISO 3297: 2007 Certified Organization)

Vol. 5, Issue 6, June 2016

$$f(x, w, b) = (w \cdot x) + b \tag{2}$$

being  $x$  the example to be classified. In the linearly separable case, learning the maximal margin hyperplane  $(w, b)$  can be stated as a convex quadratic optimization problem with a unique solution:

$$\begin{aligned} &\text{minimize } \|w\|, \\ &\text{subject to the constraints (one for each training example):} \\ &y_i((w \cdot x_i) + b) \geq 1 \end{aligned} \tag{3}$$

Vectors with non null weights are called support vectors.

## V. EXPERIMENTAL RESULTS

- Dataset :-** The sample database contains 261 fundus images of various patients and is collected from Sulochan Retina Care Center, Jalgaon. These images are taken from the fundus camera (Zeiss Company, Visualite model) and the size of image is 720x576 pixels. This dataset contains 89, 78, 57 and 37 fundus images of non-cataract, mild cataract, moderate cataract and severe cataract respectively. For training dataset, 70% of dataset is used and remaining images are used for testing purpose.
- Results :-** In this section, the comparison between proposed system and the existing system is discussed. In the proposed work, real-world dataset containing 261 fundus images is used. The system is implemented using java language and OpenCV. For testing purpose, 30% of dataset is used. Fig.3 shows the results after applying skeletonization and haar transform. Haar transform provides horizontal, vertical, diagonal and details coefficients as shown in fig. 3(c). Table 1 shows the comparison of existing system and proposed system considering various performance

Performance Measure	Existing System (%)	Proposed System (%)
Precision	73.3	77.7
Recall /Sensitivity	92.5	93
Specificity	56	77.7
F-measure	81.93	84.66

Table 1. Comparison of existing and proposed system based on various performance parameters

measures. Existing system (with MDA for classification) achieved precision as 73.3% whereas, proposed system (with SVM for classification) got precision as 77.7%. True positive rate i.e. sensitivity and true negative rate i.e. specificity achieved for proposed work is more accurate than existing system. From results, it is cleared that proposed system provides better accuracy than existing system. Here, the grades of cataract may vary due to some problems such as haemorrhages, microaneurysm, patches on retina etc.

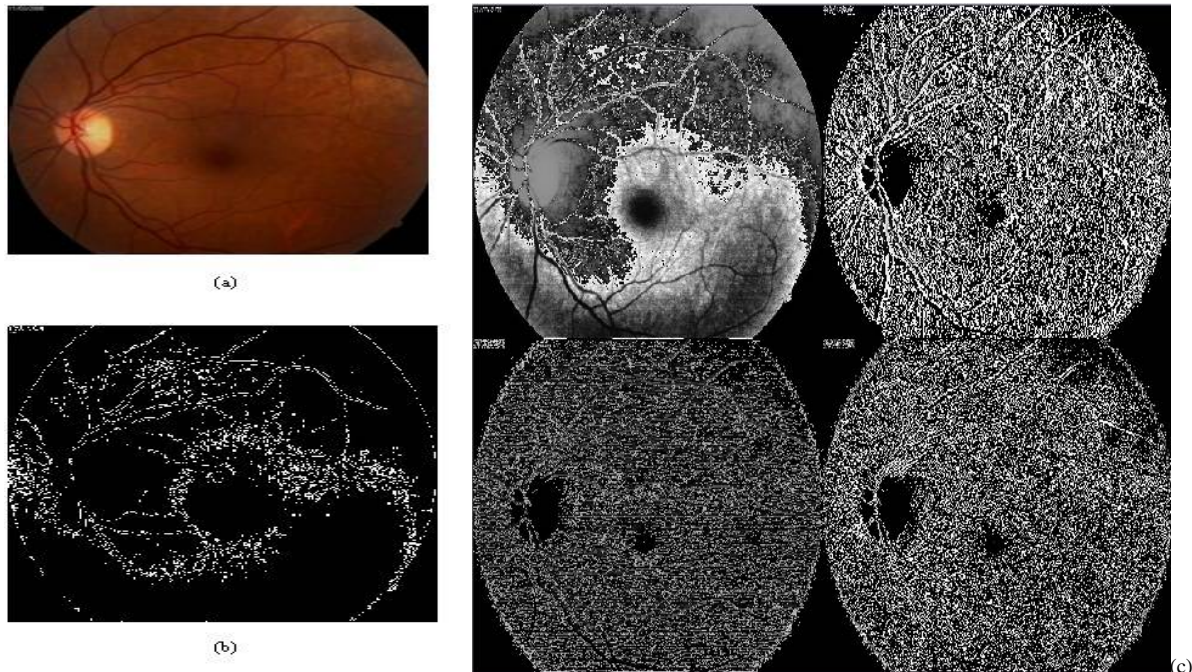


Fig. 3 Input image and its corresponding output (a) Input image (b) image after skeletonization process (c) output image after Haar transform containing horizontal, vertical, diagonal and details coefficients.

## VI. CONCLUSION

Remote cataract system is presented for detecting cataract from fundus images and providing stage of cataract to patients. The focus is to improve the accuracy of system and provide remote system so people in under-developed area can get their cataract condition timely. Features are extracted from fundus images using wavelet transform and skeletonization with DCT approach. Then extracted features are classified into two classes (cataract and non-cataract) and graded in mild, moderate and severe classes. For classification, support vector machine algorithm (SVM) is used and grading is carried out using MDA algorithm. This system is placed on Amazon cloud from which patient can efficiently access the system and get the result. SVM algorithm provides better accuracy than MDA algorithm. This system will help to reduce the workload of well-experienced ophthalmologists and help the cataract patients to know their cataract conditions. Our future work is intended to use other machine learning algorithms for better accuracy and efficiency.

## REFERENCES

- [1] C. Mathers, D. M. Fat, and J. T. Boerma, "The global burden of disease: 2004 update", World Health Organization, 2008.
- [2] S. Fan, C. R. Dyer, L. Hubbard, and B. Klein, "An automatic system for classification of nuclear sclerosis from slit-lamp photographs," in Springer Medical Image Computing and Computer-Assisted Intervention-MICCAI 2003, pp. 592-601, 2003.
- [3] H. Li, J. H. Lim, J. Liu, T. Y. Wong, A. Tan, J. J. Wang, and P. Mitchell, "Image based grading of nuclear cataract by svm regression," in Medical Imaging, pp. 691536-691536, 2008.
- [4] H. Li, J. H. Lim, J. Liu, and T. Y. Wong, "Towards automatic grading of nuclear cataract," in 29th Annual International Conference of the IEEE Engineering in Medicine and Biology Society, 2007. EMBS 2007, pp. 4961-4964, 2007.
- [5] H. Li, L. Ko, J. H. Lim, J. Liu, D. W. K. Wong, and T. Y. Wong, "Image based diagnosis of cortical cataract," in 30th Annual International Conference of the IEEE Engineering in Medicine and Biology Society, 2008. EMBS 2008, pp. 3904-3907, 2008.
- [6] H. Li, J. H. Lim, J. Liu, D.W. K.Wong, Y. Foo, Y. Sun, and T. Y. Wong, "Automatic detection of posterior subcapsular cataract opacity for cataract screening," in Annual International Conference of the IEEE Engineering in Medicine and Biology Society (EMBC), 2010, pp. 5359-5362, 2010.
- [7] Y. C. Chow, X. Gao, H. Li, J. H. Lim, Y. Sun, and T. Y. Wong, "Automatic detection of cortical and psc cataracts using texture and intensity analysis on retro-illumination lens images," in Annual International Conference of the IEEE Engineering in Medicine and Biology Society, EMBC, 2011, pp. 5044-5047, 2011.

## International Journal of Innovative Research in Science, Engineering and Technology

(An ISO 3297: 2007 Certified Organization)

Vol. 5, Issue 6, June 2016

- [8] X. Gao, H. Li, J. H. Lim, and T. Y. Wong, "Computer-aided cataract detection using enhanced texture features on retroillumination lens images," in 18th IEEE International Conference on Image Processing (ICIP), 2011, pp. 1565-1568, 2011.
- [9] Y. Xu, X. Gao, S. Lin, D. W. K. Wong, J. Liu, D. Xu, C. Y. Cheng, C. Y. Cheung, and T. Y. Wong, "Automatic grading of nuclear cataracts from slit-lamp lens images using group sparsity regression," in Medical Image Computing and Computer-Assisted Intervention-MICCAI 2013, Springer, pp. 468-475, 2013.
- [10] R. Srivastava, X. Gao, F. Yin, D. W. Wong, J. Liu, C. Y. Cheung, and T. Y. Wong, "Automatic nuclear cataract grading using image gradients," Journal of Medical Imaging, vol. 1, pp. 014502-014502, 2014.
- [11] L. Guo, J.-J. Yang, L. Peng, J. Li, and Q. Liang, "A computer-aided healthcare system for cataract classification and grading based on fundus image analysis," Computers in Industry, vol. 69, pp. 72-80, 2015.
- [12] O. Faust, R. Acharya, E. Y.-K. Ng, K.-H. Ng, and J. S. Suri, "Algorithms for the automated detection of diabetic retinopathy using digital fundus images: a review," Journal of medical systems, vol. 36, pp. 145-157, 2012.
- [13] Y. Kanagasingam, A. Bhuiyan, M. D. Abramoff, R. T. Smith, L. Goldschmidt, and T. Y. Wong, "Progress on retinal image analysis for age related macular degeneration," Progress in retinal and eye research, vol. 38, pp. 20-42, 2014.
- [14] J. Nayak, R. Acharya, P. S. Bhat, N. Shetty, and T.-C. Lim, "Automated diagnosis of glaucoma using digital fundus images," Journal of medical systems, vol. 33, pp. 337-346, 2009.
- [15] M. Niemeijer, B. Van Ginneken, M. J. Cree, A. Mizutani, G. Quellec, C. Sanchez, B. Zhang, R. Hornero, M. Lamard, C. Muramatsu, et al., "Retinopathy online challenge: automatic detection of microaneurysms in digital color fundus photographs," IEEE Transactions on Medical Imaging, vol. 29, pp. 185-195, 2010.
- [16] A. A.-H. A.-R. Youssif, A. Z. Ghalwash, and A. A. S. A.-R. Ghoneim, "Optic disc detection from normalized digital fundus images by means of a vessel's direction matched filter," IEEE Transactions on Medical Imaging, vol. 27, pp. 11-18, 2008.
- [17] M. Niemeijer, M. D. Abramoff, and B. Van Ginneken, "Fast detection of the optic disc and fovea in color fundus photographs," Medical image analysis, vol. 13, pp. 859-870, 2009.
- [18] J. V. Soares, J. J. Leandro, R. M. Cesar Jr, H. F. Jelinek, and M. J. Cree, "Retinal vessel segmentation using the 2-d gabor wavelet and supervised classification," IEEE Transactions on Medical Imaging vol. 25, pp. 1214-1222, 2006.
- [19] M. Caxinha, E. Velte, M. Santos, F. Perdigão, J. Amaro, M. Gomes, and J. Santos, "Automatic cataract classification based on ultrasound technique using machine learning: A comparative study," Physics Procedia, vol. 70, pp. 1221-1224, 2015.
- [20] M. Caixinha, E. Velte, M. Santos, and J. B. Santos, "New approach for objective cataract classification based on ultrasound techniques using multiclass svm classifiers," in 2014 IEEE International Ultrasonics Symposium (IUS), pp. 2402-2405, 2014.