

Extraction of Retinal Vasculature in Fundus Images

Safana Jasmine H¹, Rubini G², P. Kala³P.G. Scholar, Department of Medical Electronics and Engineering, PTR College of Engineering and Technology,
Austinpatty, Madurai, India¹Assistant Professor, Department of Electronics and Communication Engineering, PTR College of Engineering and
Technology, Austinpatty, Madurai, India²

ABSTRACT: The rapid and sensitive detection of retina helps in diagnosis of various ophthalmic conditions. Anatomical structure other than retina, contribute them in vision process. The measurement of retinal blood vessel morphology (i.e.) retinal vascular structure and properties related to that plays a major role in identification of various diseases such as diabetic retinopathy, hypertension, choroidal neovascularisation, atherosclerosis, glaucoma and stroke etc. Because the retinal imaging provides a snapshot of what is happening inside the human body. In this paper, the detection of vessels in fundus image of an eye using different morphological operators is the essential step in clinical process. Then the processed image is classified and vessel structures are identified. This method is less complex and computationally efficient.

KEYWORDS: Retinal imaging, morphological operators, fundus image processing, classifier.

I. INTRODUCTION

RETINA is a light-sensitive layer of tissue, lining the inner surface of the eye. The optics of the eye create an image of the visual world on the retina (through the cornea and lens), which serves much the same function as the film in a camera. It is the only part of the CNS that can be visualized non-invasively. It is a layered structure with several layers of neurons interconnected by synapses. The only neurons that are directly sensitive to light are the photoreceptor cells. These are mainly of two types: the rods and cones. Rods function mainly in dim light and provide black-and-white vision, while cones support daytime vision and the perception of colour. In adult humans, the entire retina is approximately 72% of a sphere about 22 mm in diameter. The entire retina contains about 7 million cones and 75 to 150 million rods. An image produced by the retina is patterned excitation of the cones and rods in the retina. The excitation is processed by the neuronal system and various parts of the brain working in parallel to form a representation of the external environment in the brain. The cones respond to bright light and mediate high-resolution colour vision during daylight illumination (also called photopic vision). The rods are saturated at daylight levels and don't contribute to pattern vision. The retina does not simply send a picture to the brain. The retina spatially encodes (compresses) the image to fit the limited capacity of the optic nerve. Compression is necessary because there are 100 times more photoreceptor cells than ganglion cells. Diseases and disorders of retina as follows: Diabetic eye disease can affect many parts of the eye, including the retina, macula, lens and the optic nerve. Diabetic retinopathy affects blood vessels in the light-sensitive tissue called the retina that lines the back of the eye. It is the most common cause of vision loss among people with diabetes and the leading cause of vision impairment and blindness among working-age adults. Choroidal neovascularisation (CNV) is one of the most severe causes of visual impairment in patients with uveitis. When the disruption of the homeostasis between the retinal pigment epithelium (RPE) and Bruch's membrane occurs, a vicious circle leads to the choroidal neo-angiogenesis. Both non-infectious and infectious uveitis can have CNV as a possible sequel: Infectious uveitis is due to infective agents that directly affect the retino-choroidal space whereas non-infectious uveitis is likely to be an auto inflammatory disease.

International Journal of Innovative Research in Science, Engineering and Technology

(An ISO 3297: 2007 Certified Organization)

Vol. 5, Issue 6, June 2016

Choroidal neovascularisation (CNV) involves the growth of new blood vessels that originate from the choroid through a break in the Bruch membrane into the sub-retinal pigment epithelium (sub-RPE) or sub retinal space. CNV is a major cause of visual loss. The vascular topographical geometry in the retina is known to conform to structural principles that are related to certain physical properties. The unique structure of the blood vessels in the retina has been used for biometric identification. Changes in the retinal microcirculation are seen with aging, exposure to air pollution and may indicate cardiovascular diseases such as hypertension and atherosclerosis. The paper is organized as follows; Section II describes about techniques of imaging, and its segmentation methods. Section III describes the proposed method, Section IV about experimental results of the images, Section V presents conclusion.

II. RELATED WORK

Retinal/Fundus imaging is the process whereby a 2-D representation of the 3-D retinal semi-transparent tissues projected onto the imaging plane is obtained using reflected light. Fundus images can be obtained using three methods, Fundus camera, Fluorescein angiography (FA) and Optical Coherence Tomography(OCT). It is the creation of a photograph of the interior surface of the eye, including the retina, optic disc, macula, and posterior pole. Fundus photography is widely used for population-based, large scale detection of diabetic retinopathy, glaucoma, and age-related macular degeneration. FA is a standard imaging technique used on a large scale for retinal imaging. A Fluorescein angiography is a medical procedure in which a fluorescent dye is injected into the bloodstream. The dye highlights the blood vessels in the back of the eye so they can be photographed. OCT is based on optical imaging, used specifically for optically scattering media. It is mostly used for three dimensional imaging and preparation for and follow-up in vitreoretinal surgery. It can also be obtained from three databases DRIVE, STARE, CHASE_DB1. Segmentation of these retinal images is done by invariant threshold method and feature extraction using morphological operators and Gaussian low pass filter. The green channel and L channel of image are extracted and combined using morphological operator - top hat opening and closing operations. The obtained retinal image is classified using Gaussian mixture model classifier. Then the vessel structures are identified for various pathological conditions.

III. METHODOLOGY

The images are made to undergo some morphological operations, which will produce intense monochrome image. Blood vessels in fundus images can be broadly categorized in to two kinds. The first category includes wide and thick vessels that are easily distinguishable from the neighbouring pixels based on pixel intensities. The second category includes the fine small blood vessels branches that are not very distinct against the neighbouring pixels. Then the extraction of major vessels ensures segmentation of the first category of blood vessels, while the classification of the pixels in the vessel sub image aids identification of the second category of fine vessels.

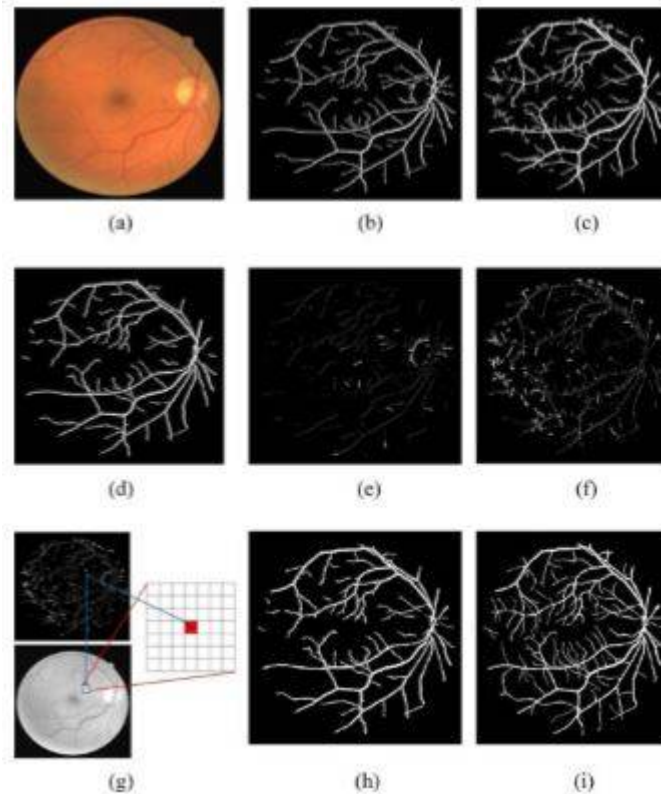
IV. EXPERIMENTAL RESULTS

Figures show the results of proposed vasculature segmentation algorithm. (a) Shows the original image. (b) Binary image from top hat reconstruction (c) Binary image from Gaussian high pass filtering (d) Major vessels intersecting between both images. (e), (f) sub image regions of both extracted images (g) feature extraction of sub image (h) Post processed vasculature after classification of sub image and combining of major vessels (i) manually marked vessels.

International Journal of Innovative Research in Science, Engineering and Technology

(An ISO 3297: 2007 Certified Organization)

Vol. 5, Issue 6, June 2016



V. CONCLUSION

Thus we have performed the vasculature of retinal images. First, the images are reconstructed using morphological operators and Gaussian filter. Later, the images are classified using Gaussian mixture model and the major portions of blood vessels are identified.

REFERENCES

- [1] Sohini Roychowdhury, Student member IEEE, Dara D, Koozekanani, Member IEEE, and Keshab K. Parhi, Fellow; IEEE. "Blood vessel segmentation of Fundus images by major vessel extraction and sub image classification" IEEE journal of Biomedical and Health Informatics, vol.19, no.3, may 2015.
- [2] Namita Sengar, Malay Kishore Dutta, M. Parthasarathi, Radim Burget "Extraction of retinal vasculature by using morphology in fundus images" international conference on signal processing and integrated networks, 2015.
- [3] Qiangfeng Peter Lau*, Mong Li Lee, Wynne Hsu, and Tien Yin Wong, "Simultaneously Identifying All True Vessels From Segmented Retinal Images" IEEE transactions on biomedical engineering, vol. 60, no.7, july 2013.
- [4] Mathers CD, Loncar D, "Projections of global mortality and burden of disease from 2002 to 2030" PLoS Med, 3(11):e442, 2006.
- [5] Michael D. Abramoff, Senior Member, IEEE, Mona K. Garvin, Member, IEEE, and Milan Sonka, Fellow, IEEE, "Retinal Imaging and Image Analysis", IEEE reviews in biomedical engineering, vol. 3, 2010.
- [6] J. Benadict Raja, C.G. Ravichandran, "Blood vessel segmentation for high resolution images", IJCSI International Journal of Computer Science Issues, vol. 8, issue 6, no 2, november 2011.
- [7] G. G. Gardner, D. Keating, T. H. Williamson, and A. T. Elliott, "Automatic detection of diabetic retinopathy using an artificial neural network: A screening tool," Br. J. Ophthalmol., vol. 80, pp. 940-944, 1996.
- [8] "Sensory Reception: Human Vision: Structure and function of the Human Eye" vol. 27, Encyclopaedia Britannica, 1987.
- [9] Patton, N., Aslam, T., MacGillivray, T., Deary, I., Dhillon, B., Eikelboom, R., Yogesan, K., Constable, I.: "Retinal image analysis: Concepts, applications and potential", Progress in Retinal and Eye Research vol. 25, pp. 99-127, 2006.



ISSN(Online): 2319-8753
ISSN (Print) : 2347-6710

International Journal of Innovative Research in Science, Engineering and Technology

(An ISO 3297: 2007 Certified Organization)

Vol. 5, Issue 6, June 2016

- [10] L.D. Hubbard, R.J. Brothers, W.N. King, L.X. Clegg, R. Klein, L.S. Cooper, A. R. Sharrett, M. D. Davis, and J. Cai, "Methods for evaluation of retinal microvascular abnormalities associated with hypertension/ sclerosis in the atherosclerosis risk in communities study," *Ophthalmology*, vol. 106, pp. 2269–2280, 1999.
- [11] T. Y. Wong, A. Shankar, R. Klein, B. E. K. Klein, and L. D. Hubbard, "Prospective cohort study of retinal vessel diameters and risk of hypertension," *BMJ*, vol. 329, pp. 799–800, 2004.
- [12] Hutchins, G.M., Miner, M.M., Boitnott, J.K., "Vessel Calibre and Branch-Angle of Human Coronary Artery Branch-Points", *Circulation Research*, 38, 572, 1976.
- [13] Stanton, A.V., Wasan, B., Cerutti, A., Ford, S., Marsh, R., Sever, P.P., Thom, S.A., Hughes, A.D., "Vascular Network Changes in the Retinal with Age and Hypertension", *J. Hypertens*, 13, 1724, 1995.