

## International Journal of Innovative Research in Science, Engineering and Technology

(A High Impact Factor, Monthly, Peer Reviewed Journal)

Visit: [www.ijirset.com](http://www.ijirset.com)

Vol. 6, Issue 11, November 2017

# Open Surgical Management of Dilated Common Bile Duct Calculus: A Study of 28 Cases

Dr. Arvind Kumar Prabhat<sup>1</sup>, Dr. Niranjana Dash<sup>2</sup>, Dr. J.M. Gadekar<sup>3</sup>, Dr. Mrs. V.J.Thipse<sup>4</sup>

P.G Student, Department of General Surgery, DVVPF'S Medical College and Hospital, Ahmednagar,  
Maharashtra, India<sup>1</sup>

Professor, Head of Unit, Department of General Surgery, DVVPF'S Medical College and Hospital, Ahmednagar,  
Maharashtra, India<sup>2</sup>

Professor and Head of Department, Department of General Surgery, DVVPF'S Medical College and Hospital,  
Ahmednagar, Maharashtra, India<sup>3</sup>

Professor, Department of General Surgery, DVVPF'S Medical College and Hospital, Ahmednagar, Maharashtra, India<sup>4</sup>

**ABSTRACT:** In the initial course of disease common bile duct (CBD) calculi are clinically silent, because of incomplete obstruction of CBD, therefore it continues to pose a conspicuous problem both to the surgeons and the patients. Calculus in the CBD most commonly results from the passage of gall stones through the cystic duct. Less frequently, they may originate in CBD itself. CBD calculus occurs in 3-14.7% of patients in whom cholecystectomies are performed.[1,2] **Aim:** Study of open surgical procedure of CBD calculus and to evaluate the plan of successful management. **Materials and Methods:** We prospectively analysed 28 cases of CBD calculus admitted in surgical ward at DVVPF's Medical College and Hospital, Ahmednagar, Maharashtra during the study period of January 2014 to January 2016. **Results:** Out of 28 cases, 16(57%) cases underwent side-to-side choledochoduodenostomy (CDD) and in 12(43%) cases choledochojejunostomy (CDJ) was performed. Out of 12 cases in which CDJ was performed, in 5 (41.67%) cases loop of jejunum and in 7(58.33%) cases Roux-en-Y configuration was performed. Ascending reflux cholangitis was reported in 3(19%) and 2(17%) cases in which CDD and CDJ (Jejunal loop configuration) was performed respectively. Stone recurrence was found in 1(8%) case in which CDJ (Jejunal loop configuration) was performed. Sump syndrome was reported in 2(12.5%) cases in which side-to-side CDD was performed. There was no therapeutic related pancreatitis reported in any case. 2(7.14%) patients died (one in CDD and another one in CDJ group), cause of death being cholangitis in both the cases. **Conclusion:**The outcomes in these two procedures i.e CDD & CDJ is similar, in the mean follow-up period of 21 months. CDD is preferred over CDJ because CDD is easier and faster to perform and allows for easy endoscopic interventions if needed in the future. Before assigning any remark on outcomes of these two procedure, further studies needs to be conducted.

**KEYWORDS:** Choledochoduodenostomy(CDD); Choledochojejunostomy(CDJ); Cholecystectomy; Sump syndrome; Cholangitis

### I. INTRODUCTION

CBD stones are often asymptomatic initially i.e silent stones. They are detected in 7-20% of patients, during workup with gall bladder calculus awaiting cholecystectomy.[3] CBD calculus occurs in 3-14.7% of patients in whom cholecystectomies are performed.[1,2]

CBD calculus most commonly results from the passage of gall bladder calculus through the cystic duct i.e : secondary stone. Less frequently, formed in CBD and biliary tree itself i.e : primary stones.

CBD calculus clinically presents as, abdominal pain, fever, jaundice, pruritus and tenderness in right hypochondrium.

# International Journal of Innovative Research in Science, Engineering and Technology

(A High Impact Factor, Monthly, Peer Reviewed Journal)

Visit: [www.ijirset.com](http://www.ijirset.com)

Vol. 6, Issue 11, November 2017

Liver enzymes and serum bilirubin level usually raised in patients of CBD calculus. So, liver function test (LFT) can be used to screen CBD calculus. Raised serum bilirubin and alkaline phosphatase level reflects CBD obstruction, although they are not highly sensitive for CBD calculus.[4,5]

USG abdomen and pelvis is sensitive in 25-63% cases of CBD calculus and its specificity is 95%.[6] In our study, USG abdomen and pelvis report was helpful in reaching at final diagnosis in 27(96.42%) cases.

ERCP is the gold standard for detection of CBD calculus. Its sensitivity and specificity are 92-95% and 90-98% respectively.[7,8] In our case series, ERCP was not performed in any cases because of non availability of equipments and also patients were financial poor. ERCP with endoscopic sphincterotomy(ES) is the gold standard treatment modality of CBD calculus.

The specificity and sensitivity of MRCP is 97% & 95% respectively for detection of CBD calculus.[9-11] In our study, MRCP was done in all cases and it yielded 100% positive report.

The open surgical approach for CBD calculus includes, choledochoduodenostomy (CDD) and choledochojejunostomy (CDJ) for dilated CBD.

CDD was first performed by **Ridel**[12] in 1888. An alternative to CDD is CDJ, which can be performed with either a loop of jejunum or using a Roux-en-y configuration. CDD is indicated in ampullary stenosis, biliary sludge, impacted or giant stones, recurrent stones requiring repeated interventions and in Funnel syndrome (distal CBD stenosis along with presence of CBD stones). Funnel syndrome is one of the most classic indication for CDD.[12]

Concept of compressive anastomosis of CDJ was first proposed by **Denans** in 1826.[13] CDJ is indicated in benign or malignant CBD obstruction or stricture. The most common indication is an obstructing periampullary mass.

## II. MATERIALS AND METHODS

Between January 1, 2014 to January 1, 2016, we prospectively analysed 28 consecutive patients with dilated CBD calculus were recruited prospectively from surgical ward, DVVPF's Medical college and Hospital, Ahmednagar, Maharashtra. Out of 28 cases, 16(57%) cases underwent side-to-side choledochoduodenostomy (CDD) and in 12(43%) cases choledochojejunostomy (CDJ) was performed. Out of 12 cases in which CDJ was performed, in 5 (41.67%) cases loop of jejunum and in 7(58.33%) cases Roux-en-Y configuration was performed. The distribution of cases were based on odd-even IPD registration number. During the study period of 3 years, 102 cases of CBD calculus were managed successfully. Out of 102 cases CBD was dilated ( $\geq 12$  mm) in 28 cases, which were managed by either CDD or CDJ. Rest of the cases were managed with T- tube drainage.

### Inclusion criteria:

- Diagnosed cases of CBD calculus which could not be medically managed.
- CBD diameter  $\geq 12$  mm.
- Age group: 32-78 years.
- Both sexes.

### Exclusion criteria:

- CBD diameter  $< 12$  mm.
- Sclerosing cholangitis

In all cases of CDD was performed, duodenum was kocherized widely to allow for a tension-free anastomosis and the CBD was dissected completely along its distal anterior surface. A longitudinal duodenotomy was made close to the bile duct along the long axis of the duodenum, perpendicular to the choledochotomy. The CBD incision was made along the long axis of the bile duct as close to the duodenum as possible and of a 2 cm length to prevent stenosis. After

# International Journal of Innovative Research in Science, Engineering and Technology

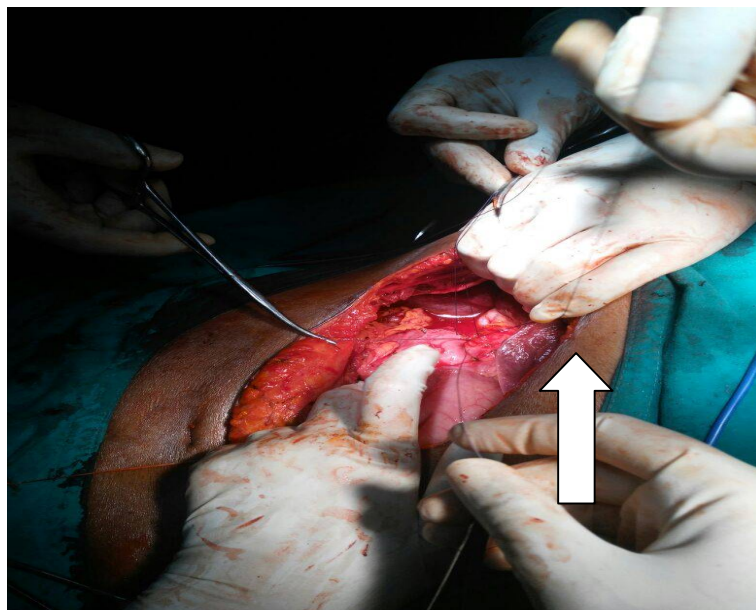
(A High Impact Factor, Monthly, Peer Reviewed Journal)

Visit: [www.ijirset.com](http://www.ijirset.com)

Vol. 6, Issue 11, November 2017

performing a CBD exploration and clearing the duct of stones, a side-to-side diamond shaped anastomosis was made with absorbable sutures, and a drain was placed for the possibility of an anastomotic leakage.

An alternative to CDD is CDJ, which can be performed with either a loop of jejunum or using a Roux-en-Y configuration. CDJ is done by bringing up a 45 cm Roux-en-Y limb of jejunum and anastomosis it end-to-side to CBD.



**Figure 1:** Intraoperative photograph: Arrow shows diamond shaped anastomosis between CBD and duodenum.

### III. RESULTS

**Table 1- Characteristics of patients**

|                            |           |
|----------------------------|-----------|
| Female                     | 20(71%)   |
| Male                       | 8(29%)    |
| Mean age (Range) in years  | 66(32-78) |
| Mean hospital stay in days | 21(18-28) |
| Hospital deaths in days    | 2(7%)     |

Values are mean and range or number of patients percentage.

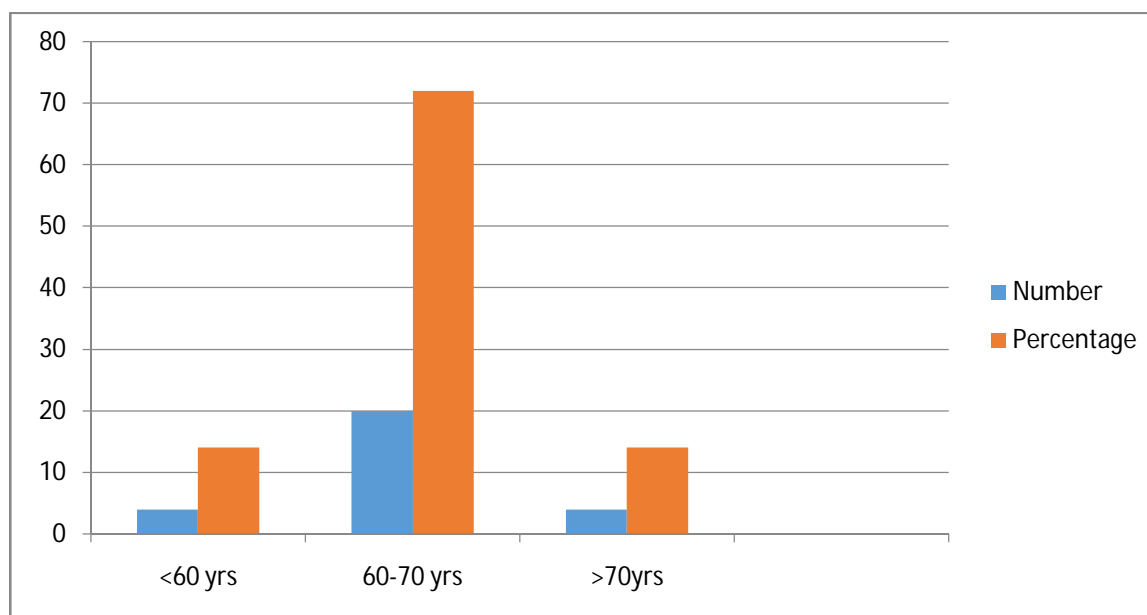
Patients characteristics are summarised in **Table 1**. There were 28 patients in the study. Out of 28 patients, 20(71%) cases were female and 8(29%) cases were males. Mean age was 66 years (range 32-78). Mean hospital stay was 21 days (range 18-28). Hospital deaths were 2(7.14%).

## International Journal of Innovative Research in Science, Engineering and Technology

(A High Impact Factor, Monthly, Peer Reviewed Journal)

Visit: [www.ijirset.com](http://www.ijirset.com)

Vol. 6, Issue 11, November 2017



**Figure 2: Distribution of age**

Majority of cases belonged to 60-70 years age group i.e 20(72%). Next in frequency was age between <60 years and >70 years. Percentage of both the age group was 14%. All deaths were in patients over 70 years old.

**Table 2: Distribution of cases as per sign and symptom**

| Clinical features                 | Number and % of patients |
|-----------------------------------|--------------------------|
| Biliary colic pain                | 28(100%)                 |
| Fever                             | 20(71.42%)               |
| Jaundice                          | 24(85.71%)               |
| Pruritis                          | 14(50%)                  |
| Tenderness in right hypochondrium | 20(71.42%)               |

All cases were presented in the surgical OPD with biliary colic pain. 20(71.42%) of cases had fever. Jaundice was present in 24(85.71%) cases. 14(50%) cases had pruritis. Tenderness in right hypochondrium was found in 20(71.42%) cases. Jaundice was absent in 4(14.28%) cases, probably due to incomplete obstruction of CBD.

**Table 3: Diagnostic tests**

| Diagnostic test        | Number and % of patients |
|------------------------|--------------------------|
| LFT                    | 25(89.28%)               |
| • Alkaline phosphatase | 24(85.71%)               |
| • Bilirubin(Direct)    | 25(89.28%)               |
| • ALT/AST              | 23(82.14%)               |
| USG abdomen            | 27(96.42%)               |
| MRCP                   | 28(100%)                 |

Liver function test (LFT) is used to screen common bile duct calculus. In biliary obstruction alkaline phosphatase and bilirubin(direct) are raised. Liver enzymes (AST & ALT) are also deranged in biliary obstruction. LFT was deranged in

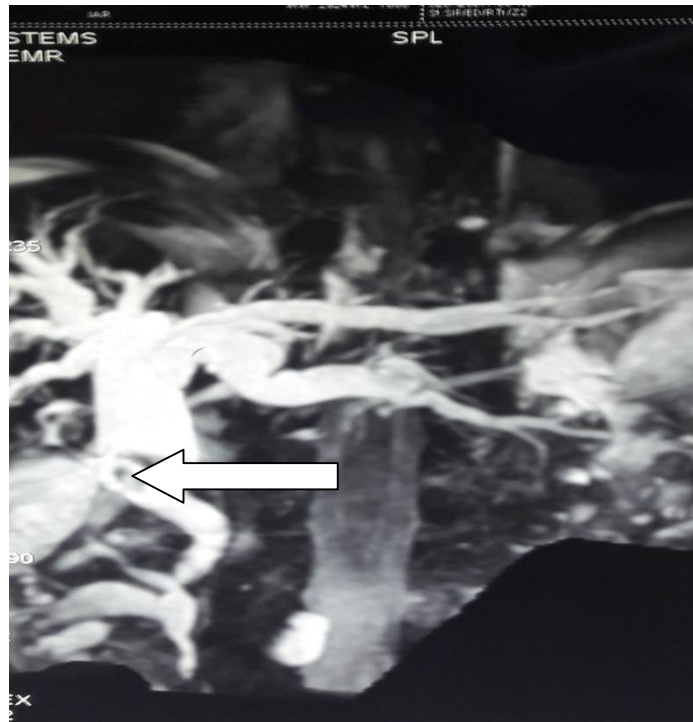
## International Journal of Innovative Research in Science, Engineering and Technology

(A High Impact Factor, Monthly, Peer Reviewed Journal)

Visit: [www.ijirset.com](http://www.ijirset.com)

Vol. 6, Issue 11, November 2017

25(89.28%) cases. In 27(96.42%) cases USG abdomen report was helpful in reaching at final diagnosis. MRCP was done in all cases, it yielded 100% positive report.



**Figure 3: MRCP:** Proximal CBD dilated showing 12X11 mm calculus just after joining of cystic duct with common hepatic duct.

**Table 4: Management and Outcomes**

Summarizes the CBD diameter, size of CBD calculus, site of CBD involved, surgical procedure and cause of morbidity and mortality.

| Serial No. | CBD diameter | CBD calculus size | Site of CBD involved | Surgical procedure   | Cause of Morbidity/ Mortality                   | Special Remarks |
|------------|--------------|-------------------|----------------------|----------------------|---|-----------------|
| 1          | 22 mm        | 15 mm             | Supraduodenal        | CDD (Side-to-side)   | Wound infection / -                             |                 |
| 2          | 18 mm        | 17 mm             | Supraduodenal        | CDD (Side-to-side)   | - / -   |                 |
| 3          | 15 mm        | 10 mm             | Retroduodenal        | CDJ(loop of jejunum) | - / -   |                 |
| 4          | 12 mm        | 12 mm             | Supraduodenal        | CDD (Side-to-side)   | - / -   |                 |
| 5          | 20 mm        | 18mm              | Retroduodenal        | CDD (Side-to-side)   | Sump syndrome/ +<br><b>(Reflux Cholangitis)</b> |                 |
| 6          | 15 mm        | 15mm              | Retroduodenal        | CDJ(loop of          | Reflux  | Stone           |

## International Journal of Innovative Research in Science, Engineering and Technology

(A High Impact Factor, Monthly, Peer Reviewed Journal)

Visit: [www.ijirset.com](http://www.ijirset.com)

Vol. 6, Issue 11, November 2017

|    |       |       |               | jejunum)               | cholangitis/ -                                       | recurrence |
|----|-------|-------|---------------|------------------------|--|------------|
| 7  | 13 mm | 12mm  | Retroduodenal | CDD (Side-to-side)     | Wound infection / -                                  |            |
| 8  | 17 mm | 15 mm | Supraduodenal | CDJ(Roux-en-Y)         | - / -  |            |
| 9  | 25 mm | 25 mm | Retroduodenal | CDD (Side-to-side)     | Wound infection / -                                  |            |
| 10 | 20 mm | 20 mm | Retroduodenal | CDJ(loop of jejunum)   | - / -  |            |
| 11 | 25 mm | 23 mm | Supraduodenal | CDD (Side-to-side)     | Reflux cholangitis/ -                                |            |
| 12 | 18 mm | 18 mm | Retroduodenal | CDJ (loop of jejunum ) | Reflux cholangitis/ +<br><b>(Reflux cholangitis)</b> |            |
| 13 | 20 mm | 18 mm | Infraduodenal | CDD (Side-to-side)     | - / -  |            |
| 14 | 25 mm | 20 mm | Retroduodenal | CDD (Side-to-side)     | Wound infection / -                                  |            |
| 15 | 13 mm | 12 mm | Retroduodenal | CDD (Side-to-side)     | Reflux cholangitis/ -                                |            |
| 16 | 12 mm | 12 mm | Retroduodenal | CDD (Side-to-side)     | Sump syndrome/ -                                     |            |
| 17 | 20 mm | 20 mm | Retroduodenal | CDD (Side-to-side)     | Bile leak/ -   |            |
| 18 | 16 mm | 12 mm | Infraduodenal | CDD (Side-to-side)     | - / -  |            |
| 19 | 12 mm | 10 mm | Retroduodenal | CDJ(Roux-en-Y)         | - / -  |            |
| 20 | 22 mm | 20 mm | Supraduodenal | CDJ(loop of jejunum)   | - / -  |            |
| 21 | 20 mm | 19 mm | Retroduodenal | CDD (Side-to-side)     | Wound infection / -                                  |            |
| 22 | 26 mm | 20 mm | Retroduodenal | CDJ(Roux-en-Y)         | - / -  |            |
| 23 | 13 mm | 12 mm | Infraduodenal | CDJ(Roux-en-Y)         | - / -  |            |
| 24 | 18 mm | 18 mm | Retroduodenal | CDJ(Roux-en-Y)         | - / -  |            |
| 25 | 21 mm | 20 mm | Infraduodenal | CDD (Side-to-side)     | - / -  |            |
| 26 | 12 mm | 12 mm | Retroduodenal | CDJ(Roux-en-Y)         | - / -  |            |
| 27 | 25 mm | 20 mm | Supraduodenal | CDJ(Roux-en-Y)         | - / -  |            |
| 28 | 21 mm | 20 mm | Retroduodenal | CDD (Side-to-side)     | - / -  |            |

CDD was performed in 16(57%) cases and CJD in 12(43%) cases. Morbidity includes wound infection in 4(14.28%) cases and bile leak in 1(3.57%) case. Sump syndrome was reported in 2(12.5%) cases in which side-to-side CDD was performed. Ascending reflux cholangitis was reported in 3(19%) and 2(17%) cases in which CDD and CDJ was performed respectively. Stone recurrence was found in 1(8%) case in which CDJ was performed. 2(7.14) patients died(one each in CDD & CDJ), cause of death being cholangitis. CDJ was performed in 12(43%) cases. In 5 (41.67%) cases loop of jejunum and in 7(58.33%) cases Roux-en-Y configuration was performed. Ascending reflux cholangitis was reported in 2(17%) cases of jejunal loop configuration of CDJ.



# International Journal of Innovative Research in Science, Engineering and Technology

(A High Impact Factor, Monthly, Peer Reviewed Journal)

Visit: [www.ijirset.com](http://www.ijirset.com)

Vol. 6, Issue 11, November 2017

## IV. DISCUSSION

In the initial course of disease, CBD calculus is silent. Clinically patients ranges from completely asymptomatic to complications such as, pancreatitis or cholangitis. According to **Rooseland and T.B. Glomsaker**[14] CBD calculus are asymptomatic in 5.2-12% of cases. However in our study, all the cases were symptomatic. CBD calculus occurs in 3-14.7% of patients in whom cholecystectomies are performed.[1,2] In our study, CBD calculus was found in 3(10.71%) cases in whom cholecystectomies was performed. CBD calculus clinically presents as, abdominal pain, fever, jaundice, pruritus and tenderness in right hypochondrium. All these symptoms were present in patients of our study.

Liver enzymes and serum bilirubin level usually raised in patients of CBD calculus. So, LFT can be used to screen CBD calculus. Raised levels of direct serum bilirubin and alkaline phosphatase reflects biliary obstruction, but these are neither highly specific nor highly sensitive for CBD calculus. In our study, LFT deranged in 25(89.28%) cases [Direct serum bilirubin and alkaline phosphatase raised in 25 (89.28%) and 24(85.71%) cases respectively]. Jaundice was present in 24(85.71%) cases. Jaundice was absent in 4(14.28%) cases, probably due to incomplete obstruction of CBD.

**M. Sugiyoma and Y. Atomi**[15] study showed, specificity of USG abdomen is 95% in cases of CBD calculus. In the present case series, there was 96.42% specificity. These results are same as our case series study.

**J. Romagnuolo et al**[10] study showed sensitivity and specificity of MRCP is 95% & 97% respectively for demonstrating CBD calculus. In this present series, MRCP was done in all cases and it yielded 100% positive results.

The gold standard treatment modality for CBD calculus is ERCP with endoscopic sphincterotomy(ES). **Martin et al** reported open surgical approach is more successful with a lesser mortality than ERCP with ES.[16] Open surgical approach was used in our study and has got good results. However, when different modality have failed then open surgical approach remains as a final option and it produces good results. CDD & CDJ are two main open surgical approach.

The first successful choledochoduodenostomy(CDD) operation was performed by **Sprengel** in 1891. The side-to-side anastomosis is the most commonly used technique in CDD, but an end-to-side is also an option. In our study, in all cases in which CDD was done, side-to-side anastomosis was used. Diameter of CBD of atleast 1.2 cm along with placing the anastomosis near the duodenum is important in assessing the feasibility of CDD because this allows a wide enough stoma to ensure good biliary drainage and avert stenosis. Stomal patency is most important factor for preventing both sump syndrome and reflux cholangitis.[17] In our case series, diameter of CBD in all cases were more than or equal to 1.2 cm and anastomosis was done near the duodenum. In spite of all precaution taken during anastomosis, sump syndrome and reflux cholangitis were found in 2(12.5%) cases and 3(19%) cases respectively, it is probably due to patient in compliance and individual variation or difficult to explain, so it needs further study.

The mortality and morbidity rates associated with CDD are 3% and 23% respectively.[12] Mortality is most commonly from medical conditions, such as myocardial infarction, heart failure and pulmonary embolism. In our case series, mortality was reported in 1(6.25%) case. Cause of death being pneumonitis, probably secondary to ascending reflux cholangitis. Most common cause of morbidities are cholangitis and sump syndrome. In our study, cause of morbidities were wound infection, bile leak, sump syndrome and reflux cholangitis.

The incidence of cholangitis ranges from 0-6% in the largest long-term followup series.[12] In our case series, reflux cholangitis was reported in 19% of cases in which CDD was performed in 21 months of followup. Our case series study data is quite higher than what quoted in the literature. Disparity in these two results is difficult to explain.

**Deutsch and colleagues**[18] reported mortality rate of 4% in which CDD was performed. All deaths occurring in patients over 70 years old. In our series, mortality rate was 6.25% and age of patient was 76 years. In **Deutsch and colleagues** study, cause of morbidities were wound infections in 18(14%) cases and bile leak in 4(3%) patients. In our study, wound infection was found in 4(14.28%) cases and bile leak in 1 (3.57%) case. These results are similar as our case series study.

# International Journal of Innovative Research in Science, Engineering and Technology

(A High Impact Factor, Monthly, Peer Reviewed Journal)

Visit: [www.ijirset.com](http://www.ijirset.com)

Vol. 6, Issue 11, November 2017

An alternative to CDD is CDJ, which can be performed with either a loop of jejunum or using a Roux-en-Y configuration. In our study, CDJ was performed in 12 (43%) cases. In 5(41.67%) cases loop of jejunum and in 7 (58.33%) cases Roux-en-Y configuration was performed.

**Gouma and Colleagues**[19] reported their experience with 43 cases undergoing Roux-en-Y CDJ configuration. There was only one major complication and no mortality. In our case series, Roux-en-Y CDJ configuration was performed in 7 (58.33%) cases, in which no any complication and mortality were reported. Out of 12 cases of CDJ, loop of jejunum configuration was performed in 5(41.67%) cases. Ascending reflux cholangitis was reported in 2(17%) cases and one patient died, Cause of death being cholangitis. Stone recurrence was found in 1(8%) case.

A French group **Panis Y et al**[20] evaluated a comparison between CDD & CDJ for choledocholithiasis. Of the 120 patients CDD & CDJ were performed in 58 and 62 patients, which were followed upto a period of 29 months. 107 patients were symptom free and 13 patients (6 CDD & 7 CDJ) experienced cholangitis. In our case series of 28 cases, CDD was performed in 16(57%) cases and CDJ in 12 (43%) cases, mean followup period was 21 months. 22 patients were symptom free. 5 patients (3 CDD & 2 CDJ) experienced cholangitis. In **Panis Y et al** study, in CDD group the cholangitis was secondary to sump syndrome in 3 cases, anastomotic stricture in one patient and unknown cause in 2 patients. In our case series of CDD group the cholangitis in 2 cases were due to sump syndrome and unknown cause in one case. In **Panis Y et al** study, in CDJ group, cholangitis was secondary to anastomotic stricture in 3 patients, residual/recurrent stone in one patient and unknown cause in 3 patients. In our case series of CDJ group the cholangitis in one patient was due to recurrent stone and in another case cause was unknown. The outcomes in terms of mortality and morbidity in **Panis Y et al** study and our case series study were in close proximity and there was no difference in mortality and morbidity was noted between these two group (CDD & CDJ).

## V. CONCLUSION

The management of CBD calculus is complicated. It continue to pose a significant problem to the surgeons in the management of CBD calculus. The gold standard treatment modality of CBD calculus is ERCP with endoscopic sphincterotomy(ES). However, when different modalities of treatment have failed then open surgical approach remains as a final option specially in dilated CBD and it produces good results. The diameter of CBD is of critical importance and should be atleast 12 mm. Meticulous and precise suturing techniques are also very important. If these precautions are taken into consideration, cholangitis and symptoms related to sump syndrome are absent or occurs very infrequently. CDD & CDJ are two open surgical approach. Very few literatures compaired the outcomes of these two procedure. So, before assigning any remark on outcomes of these two procedure, further studies needs to be conducted.

## Footnotes

Conflict of interest-None

Funding- None

## REFERENCES

- [1] Schirmer B, Winters KL, Edlich RF. Cholelithiasis and cholecystitis. J Long-Term Effects of Medical Implants. 2005;15(3):329-38.
- [2] Riciardi R, Islam S, Canete JJ, Arcand PL, Stoker ME. Effectiveness and long-term results of laparoscopic common bile duct exploration. Surg Endosc. 2003;17(1):19-22.
- [3] Verbesey JE, Birkett DH. Common bile duct exploration for choledocholithiasis. Surgical clinics of North America 2008;88(6):1315-1328.
- [4] Peng WK, Sheikh Z, Paterson-Brown S, Nixon SJ. Role of liver function tests in predicting common bile duct stones in acute calculous cholecystitis. Br J Surg. 2005;92(10):1241-7.
- [5] Sgourakis G, Dedemadi G, Stamatelopoulos A, Leandros E, Voros D, Karaliotas K. Predictors of common bile duct lithiasis in laparoscopic era. World J Gastroenterol. 2005;11(2):3267-72.
- [6] Caddy GR, Tham TCK. Symptoms, diagnosis and endoscopic management of common bile duct stones. Best Practice & Research: Clin Gastroenterol. 2006;20(6):1085-101.
- [7] Laokpessi A, Bouillet P, Sautereau D, Cessot F, Desport JC, Le Sidaner A. Value of magnetic resonance cholangiography in the preoperative diagnosis of common bile duct stones. Am J Gastroenterolo. 2001;96(8):2354-9.



## International Journal of Innovative Research in Science, Engineering and Technology

(A High Impact Factor, Monthly, Peer Reviewed Journal)

Visit: [www.ijirset.com](http://www.ijirset.com)

Vol. 6, Issue 11, November 2017

- [8] National Institute of Health. NIH state-of-the-science statement on endoscopic retrograde cholangiopancreatography (ERCP) for diagnosis and therapy. NIH Consensus and State-of-the Science Statements. 2002;19(1):1-26.
- [9] Tse F, Barkun JS, Barkun AN. The elective evaluation of patients with suspected choledocholithiasis undergoing laparoscopic cholecystectomy. *Gastrointestinal Endoscopy*. 2004;60(3):437-448.
- [10] Romagnuolo J, Bardou M, Rahme E, Joseph L, Reinhold C, Barkun AN. Magnetic resonance cholangiopancreatography: a meta-analysis of test performance in suspected biliary disease. *Annals of Internal Medicine*. 2003;139(7):547-557.
- [11] Deprez P. Approach of suspected common bile duct stones: endoscopic ultrasonography. *Acta Gastro-Enterologica Belgica*. 2000;63(3):295-298.
- [12] de Aretxabala X, Bahamondes JC. Choledochoduodenostomy for common bile duct stones. *World J Surg*. 1998;22:1171-1174.
- [13] Hardy KJ. Non-suture anastomosis: the historical development. *Aust N Z J Surg* 1990;60:625-633.
- [14] Rosseland AR, Glomsaker TB. Asymptomatic common bile duct stones. *Eur J Gastroenterol Hepatol*. 2000;12(11):1171-3.
- [15] Sugiyama M, Atomi Y. Endoscopic ultrasonography for diagnosing choledocholithiasis: a prospective comparative study with ultrasonography and computerized tomography. *Gastrointest Endosc*. 1997;45(2):143-6.
- [16] Martin DJ, Vernon DR, Toouli J. Surgical versus endoscopic treatment of bile duct stones. *Cochrane Database Syst Rev*. 2006;19;(2):CD003327.
- [17] de Aretxabala X, Bahamondes JC. Choledochoduodenostomy for common bile duct stones. *World J Surg*. 1998;22(11):1171-1174.
- [18] Deutsch AA, Nudelman I, Gutman H, Reiss R. Choledochoduodenostomy an important surgical tool in the management of common bile duct stones: a review of 126 cases. *Eur J Surg*. 1991;157:531-533.
- [19] Gouma DJ, Konsten J, Soeters PB, et al. Long-term follow-up after choledochojejunostomy for bile duct stones with complex clearance of the bile duct. *Br J Surg*. 1989;76:451-453.
- [20] Panis Y, Fagniez PL, Brisset D, et al. Long term results of choledochoduodenostomy Vs choledochojejunostomy for choledocholithiasis. The French Association for Surgical Research. *Surg Gynecol Obstet*. 1993;177:33-37.