

International Journal of Innovative Research in Science, Engineering and Technology

(A High Impact Factor, Monthly, Peer Reviewed Journal)

Visit: www.ijirset.com

Vol. 8, Issue 8, August 2019

A Study of Orthodontic Problems in Patients of Type 2 Diabetes Mellitus

¹Laxmi Kumari Yadav, ²Kavita Kumari

¹Assistant Professor, Zoology, SPC Government College, Ajmer, Rajasthan, India

²Assistant Professor, Chemistry, SPC Government College, Ajmer, Rajasthan, India

ABSTRACT: Diabetes mellitus (DM) is a metabolic disorder diagnosed in approximately 3% to 4% of the population. The disease is characterized by chronic hyperglycemia caused by a deficient insulin management. Persistently elevated blood glucose concentration gives rise to acute and chronic complications with damage to various organs. Two main types of DM exist: type 1 DM, being a total deficiency in insulin secretion, and type 2 DM, which is a combination of resistance to insulin action and inadequate compensatory insulin secretion. Since DM cannot yet be cured, the symptoms of the disease and its complications can only be treated. The sooner the disease is diagnosed, the better the prognosis of the patient, since complications in the early stage of the disease are less severe and more readily treated. As a member of the health care team, the dental practitioner should have knowledge of oral manifestations of DM to recognize initial symptoms of the disease. Also when treating DM patients, the practitioner must understand the consequences of the controlled disease in relation to orthodontic treatment.

KEYWORDS: Diabetes mellitus, type, orthodontic, manifestations, oral, dental, disease, practitioner

I. INTRODUCTION

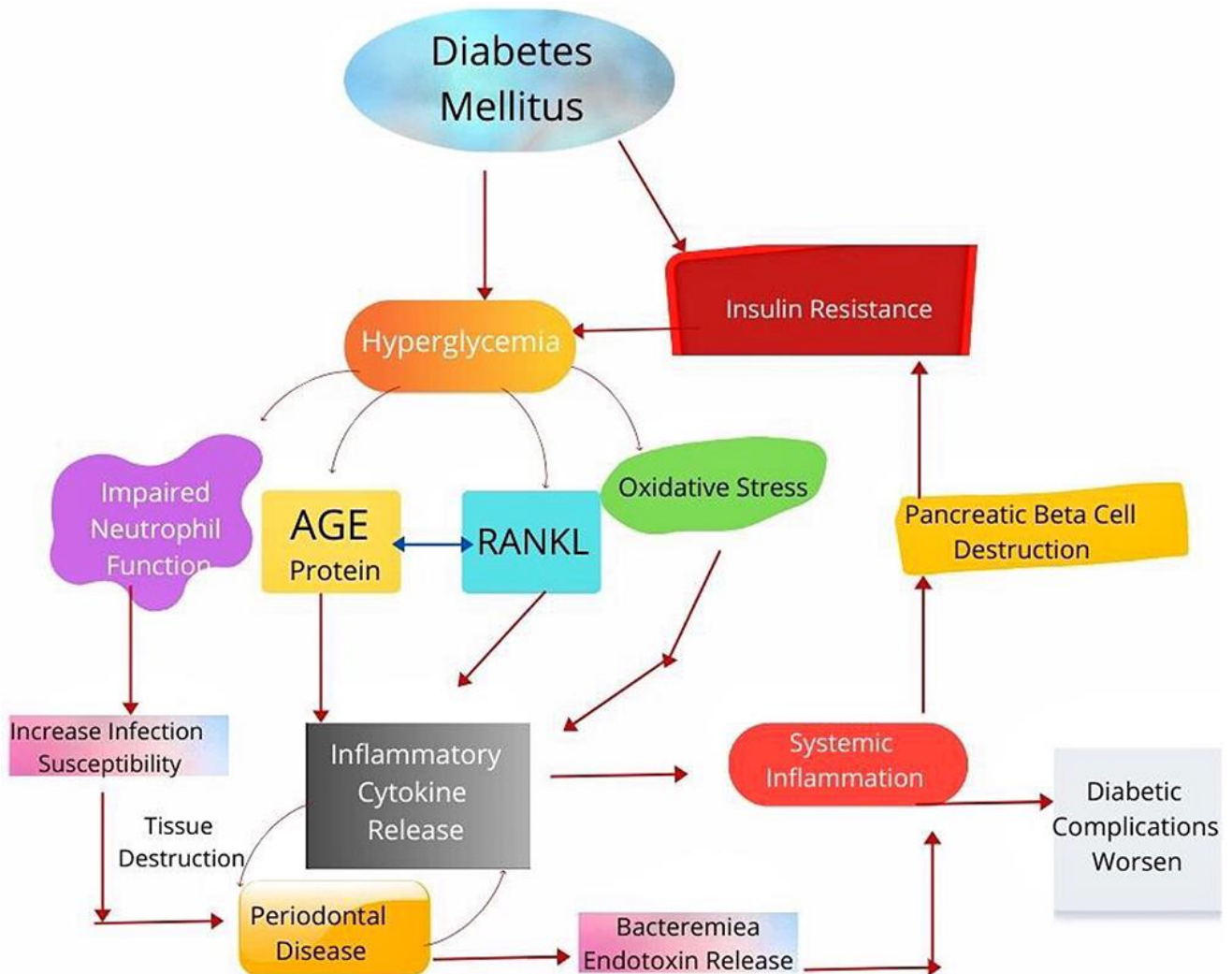
Type 2 diabetes mellitus, starts insidiously commonly beyond the age of 40 years as a result of a combination of insulin resistance, glucagon excessive secretion and insulin inadequate secretion from pancreatic beta cells of Langerhans. [1] Type 2 diabetes mellitus is also called “maturity onset diabetes” or “non-insulin-dependent diabetes mellitus (NIDDM)”. Many patients may be first diagnosed with diabetes at their dentist clinic. Common oral symptoms of diabetes include mouth dryness and burning (xerostomia), oral acetone smell in cases of poorly controlled diabetes, brittle teeth, dental caries, oral candida, mouth ulcerations, altered taste sensation, delayed healing of accidentally injured mucous membranes, and recurrent frequent infections. Diabetes also commonly destroys periodontal tissue leading to teeth disposition and misalignment. The eroded tissue results in the development of periodontitis and gingivitis. [2,3] The key for treating orthodontic problems in diabetic patients is good medical control. If patient is not in good metabolic control (HbA1c more than 9%), every effort should be made to improve blood glucose control. Orthodontic treatment should be avoided in patients with poorly controlled Insulin-dependent DM as these patients are particularly susceptible to periodontal breakdown. There is no upper age limit for orthodontic treatment. There is no treatment preference with regard to fixed or removable appliances. It is important to stress good hygiene, especially when fixed appliances are used. Daily rinses with fluoride mouthwash can provide further benefits. Diabetes related microangiopathy can occasionally occur in the periapical vascular supply resulting in unexplained odontalgia, percussion sensitivity, pulpitis or even loss of vitality. Orthodontist should be aware of this phenomenon and regular vitality checkups are advised. In adults especially it is important to evaluate periodontal status before initiating orthodontic treatment.

International Journal of Innovative Research in Science, Engineering and Technology

(A High Impact Factor, Monthly, Peer Reviewed Journal)

Visit: www.ijirset.com

Vol. 8, Issue 8, August 2019



If plaque control is difficult to achieve with mechanical aids like toothbrush and interdental aids, chlorhexidine mouthwash should be used. To minimize neutralizing effect of the chlorhexidine molecule, there should be at least a 30-minute interval between tooth brushing and the chlorhexidine rinse.[4,5] The most common dental office complication seen in diabetic patients taking insulin is symptomatic low blood glucose or hypoglycemia. The clinician should question diabetic patients about past episodes of hypoglycemia. Hypoglycemia is more common in patients with better glycemic control. When planning dental treatment, it is best to schedule appointments before or after periods of peak insulin activity. This requires knowledge of the pharmacodynamics of the drugs being taken by the diabetic patient. Morning appointment is preferable. If a patient is scheduled for a long treatment session e.g. about 90 minutes, he or she should be advised to eat a usual meal and take the medication as usual. This is important to avoid hypoglycemic reaction. When a hypoglycemic reaction occurs in the dental office, the orthodontist should recognize the symptoms and act appropriately. Most patients are familiar with these symptoms and can tell orthodontist in time. The cooperative and conscious patient who demonstrates clinical symptoms of hypoglycemia should be given high carbohydrate beverage such as orange juice. Management of the unconscious patient includes airway maintenance, oxygen administration and monitoring of vital signs. Children with diabetes are at nutritional risk and should undergo

International Journal of Innovative Research in Science, Engineering and Technology

(A High Impact Factor, Monthly, Peer Reviewed Journal)

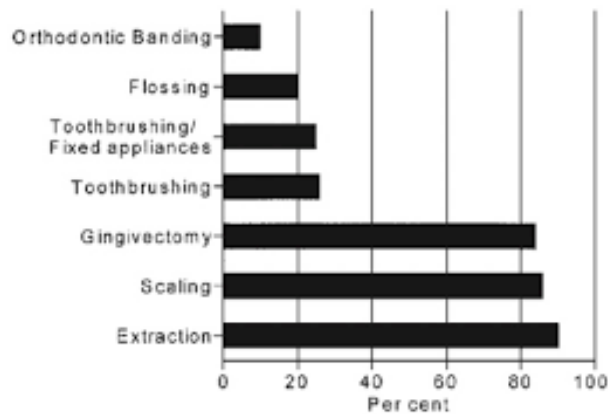
Visit: www.ijirset.com

Vol. 8, Issue 8, August 2019

nutrition screening to identify those who require formal nutrition assessment with development of a nutrition care plan. DM may adversely affect bone remodeling and tooth movement during application of orthodontic forces.[6,7] However, more long-term and well-designed studies are required before the exact mechanism and impact of DM on outcomes of orthodontic treatment is understood.

III. DISCUSSION

Regular feedback and evaluation of patient satisfaction level is essential in order to further improve quality of services.



Orthodontics and medically compromised patients

Orthodontist should be conscious about the importance of diabetes in relation to the patients' susceptibility to periodontitis, especially if uncontrolled. Periodontal health and proper oral hygiene should be strictly observed during treatment. Research has shown that people with diabetes are more likely to develop periodontal disease. Periodontal disease is a serious health problem that can lead to bone and tooth loss if not properly managed. Periodontitis (an advanced stage of gum disease) can make blood sugar levels spike and fluctuate.[8,9] Additional research suggests that when diabetic patients gain control of gum disease, they can also gain better control of their diabetes. Many patients with diabetes needs orthodontic treatment. When bone is lost surrounding teeth, often these teeth move into undesirable positions. Bone loss in the presence of inflammation, as found in periodontitis, can result in unpredictable orthodontic tooth movement during orthodontic treatment. "A diabetic patient seeking orthodontic treatment can be stable with blood sugars under control with proper monitoring. These patients can maintain their periodontal health well, as long as they are on a good oral hygiene maintenance schedule, both at home and professionally. Once these are established, they can begin orthodontic treatment." Oral hygiene maintenance and beautifully white straight teeth will help you prevent the danger of of diabetes associated periodontal disease. Let your periodontist and orthodontist help you achieve a beautiful smile.[10,11]

Diabetes increases the risk of gum disease since diabetic patients are more susceptible to infections. And people with periodontal disease face problem during their orthodontic treatment. This is how:

1. Bone loss and inflammation during periodontitis move the teeth into an undesirable position during the treatment.
2. Periodontitis stresses the gums and complicates the orthodontic treatment forcing you to stop it early.

Gingivitis – Gingivitis is the early stage of gum periodontal disease that results in red, swollen and tender gums. It makes the gums bleed easily and also results in bad breath.

International Journal of Innovative Research in Science, Engineering and Technology

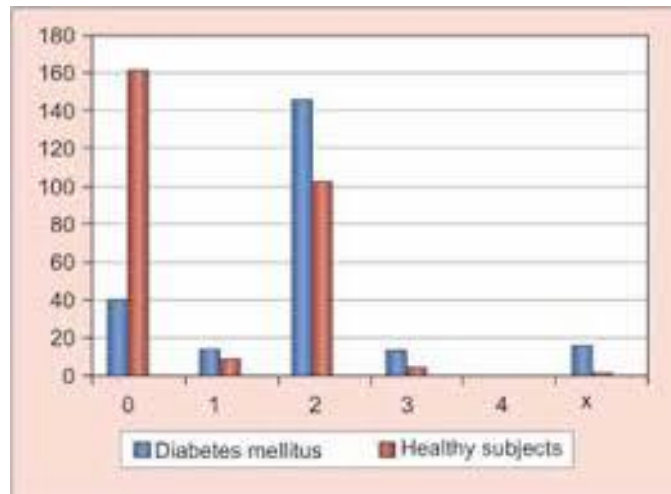
(A High Impact Factor, Monthly, Peer Reviewed Journal)

Visit: www.ijirset.com

Vol. 8, Issue 8, August 2019

Low saliva levels and high glucose levels due to diabetes make our mouth more vulnerable to oral infections, particularly fungal infection also known as thrush. And if you're undergoing orthodontic treatment, infections can get worse. Moreover, diabetes reduces the production of saliva in your mouth which can leave you feeling thirsty all the time.

We can't deny that diabetes has become a common disease, but that doesn't make it any less serious. It exposes you to the risk of developing heart diseases and affects your eyes, kidneys, nerves and even skin. But what's often ignored is how diabetes affects your oral health which highly influences your orthodontic treatment. Keep reading to find out the threats of diabetes to your oral health.[12]



Oral health evaluation in type-2 diabetes patients

Diabetes and Periodontal Disease

Periodontitis is a gum infection which affects the soft tissue and destroys the bone that supports the teeth. It is caused by the build-up of bacteria in your mouth and may result in the loss of teeth. To put it simply, it is caused by poor oral healthcare.[13]

Periodontal Disease and Orthodontic Treatment

Diabetes increases the risk of gum disease since diabetic patients are more susceptible to infections. And people with periodontal disease face problem during their orthodontic treatment. This is how:

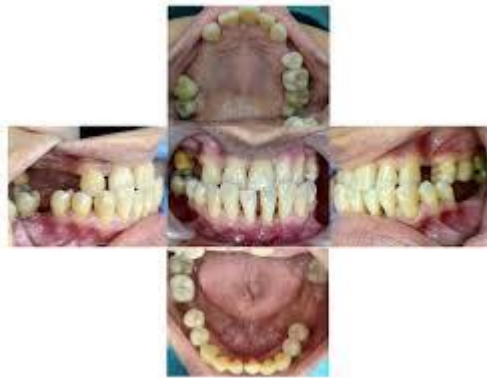1. Bone loss and inflammation during periodontitis move the teeth into an undesirable position during the treatment.
2. Periodontitis stresses the gums and complicates the orthodontic treatment forcing you to stop it early.

International Journal of Innovative Research in Science, Engineering and Technology

(A High Impact Factor, Monthly, Peer Reviewed Journal)

Visit: www.ijirset.com

Vol. 8, Issue 8, August 2019



Progressive periodontitis stage iv in diabetes type 2 patient

Gingivitis – Gingivitis is the early stage of gum periodontal disease that results in red, swollen and tender gums. It makes the gums bleed easily and also results in bad breath.

Gingivitis and Orthodontic Treatment

1. Gingivitis results in swelling in the gums. This brings the capillaries closer to the surface leading to bleeding if traditional braces accidentally tear the skin.
2. Swelling in gums can obstruct the brackets if left untreated.

Tooth Decay

The most common of the oral health problems is tooth decay. It is caused by bacteria feeding on the sugar in your mouth which results in the accumulation of plaque over the surface of teeth. The saliva in our mouth balances the acid produced by the bacteria. However, due to high saliva and blood glucose levels in diabetic patients, the saliva fails to balance the acid.[14,15]

Tooth Decay and Orthodontic Treatment

1. The brackets and wires in your braces easily trap the food particles. And poor oral care during the orthodontic treatment results in permanent damage to your teeth making them brown and chalky.
2. The loss of mineral of the tooth structure can even make the teeth crumble and break.

Oral Infections and Dry Mouth

Low saliva levels and high glucose levels due to diabetes make our mouth more vulnerable to oral infections, particularly fungal infection also known as thrush. And if you're undergoing orthodontic treatment, infections can get worse. Moreover, diabetes reduces the production of saliva in your mouth which can leave you feeling thirsty all the time.

International Journal of Innovative Research in Science, Engineering and Technology

(A High Impact Factor, Monthly, Peer Reviewed Journal)

Visit: www.ijirset.com

Vol. 8, Issue 8, August 2019

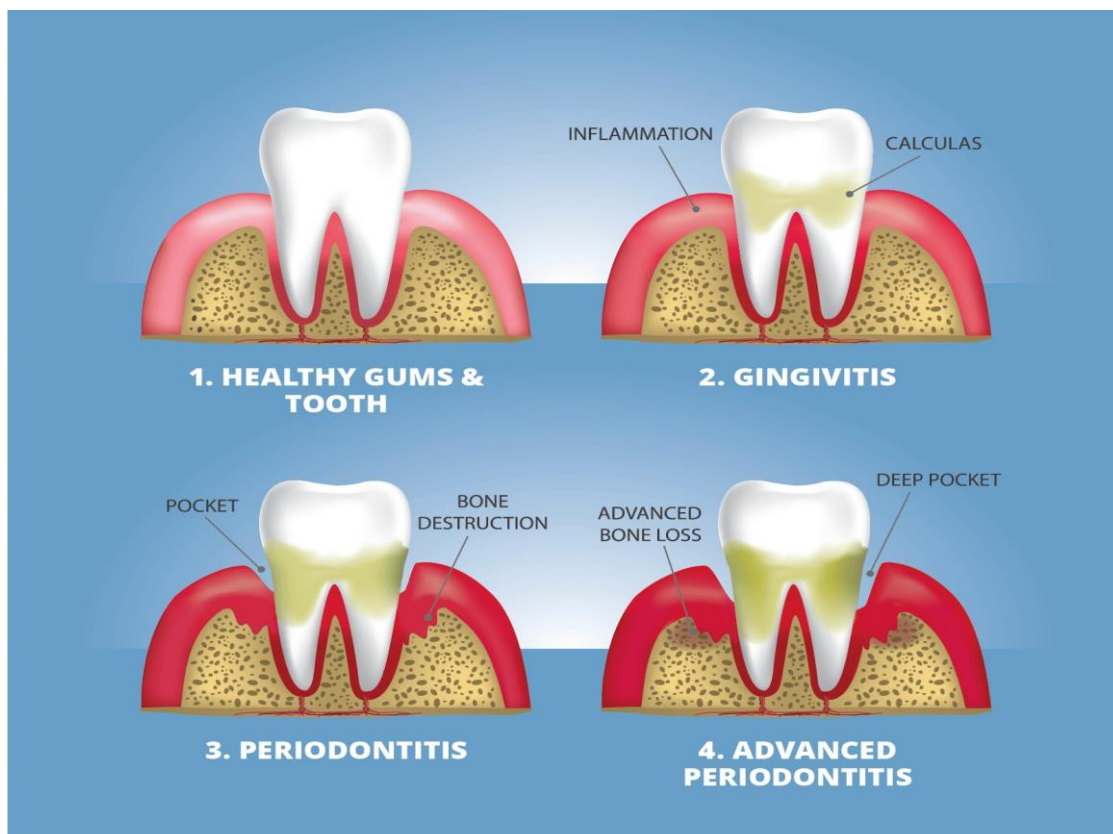
Oral Healthcare for Diabetic Patients

1. Use an interdental brush. It is thin, round or cone-shaped brush with bristles held together by a wire. It is designed to be inserted between the teeth gently.
2. Brush your teeth twice a day and complete your oral routine by a mouthwash to remove bacteria.
3. Rinse your mouth after every meal.
4. Drink water along with food to wash away the tiny food particles immediately.
5. Check your mouth regularly for signs of gum disease such as inflammation, redness, or bleeding gums.
6. Don't smoke.

Traditional orthodontic treatment using wires can get complicated for people with diabetes. The alternative to braces is the Invisalign treatment which aligns the teeth using transparent Invisalign holders. It helps maintain good oral health since you can remove and put an Invisalign holder back on before and after every meal.

IV. RESULTS

There is currently a paucity of solid evidence with regard to alterations of the equilibrium of the implicated structures under the status of diabetes mellitus, when mechanical stimulation of teeth is attempted, with sporadic inferences from animal research. Significant research insights in how the disease impacts on orthodontic tooth movement are invaluable, at present. Severe gum disease (periodontitis) can cause diabetes.



International Journal of Innovative Research in Science, Engineering and Technology

(A High Impact Factor, Monthly, Peer Reviewed Journal)

Visit: www.ijirset.com

Vol. 8, Issue 8, August 2019

Diabetes and dental problems

According to researchers at Marquette University, “Periodontitis may [raise levels of inflammatory cytokines and serum lipids]. These cytokines can produce an insulin resistance syndrome similar to that observed in diabetes and initiate destruction of pancreatic beta cells leading to development of diabetes.” Gum infections can raise blood glucose levels. At the same time, high blood glucose makes it harder to fight infections. People with diabetes, especially uncontrolled diabetes, have more gum disease than those without diabetes. We have known that for a long time. Now, scientists are finding that gum disease may raise blood sugar levels in people with and without diabetes. At a recent meeting of top experts in dental and diabetes research from around the world, scientists looked closely at the latest research into how gum disease could affect diabetes. They found that, compared with those with healthy gums, people with severe gum disease have higher long-term blood sugar levels (A1c); might be at a higher risk of developing type 2 diabetes; may be at a higher risk of developing pregnancy (gestational) diabetes; have a harder time controlling their type 2 diabetes; dare at a higher risk of experiencing harm to eyes and kidneys, as well as a heart attack and stroke if they have diabetes. Scientists think that some of the germs in infected gums leak into the bloodstream after normal activities such as chewing or toothbrushing. [16] This starts a reaction from your body’s defense system, which, in turn, produces some powerful molecules that have harmful effects all over your body. An example is raising your blood sugar level. Keep your gums as healthy as possible, whether or not you have diabetes. Brush your teeth gently twice a day with a soft-bristled brush and a fluoride toothpaste. Clean between your teeth with floss or another interdental cleaner daily. Visit your dentist regularly for checkups and cleanings. Make sure you have your gums checked; the dentist or dental hygienist should measure the space between the teeth and the gums to look for gum disease. If you have type 2 diabetes, keeping your gums healthy could help you control your disease. It also may help lower your risk of experiencing problems, such as blindness and kidney disease, because of your diabetes. The latest research on links between gum disease and diabetes shows how important it is to have healthy gums. A healthy mouth is an important part of good overall health.[17]

V. CONCLUSIONS

A vicious circle exists between diabetes and gum disease. The presence of inflammation anywhere in the body can raise blood sugar in people with Type 2 diabetes. Diabetes increases the chance of a bacterial infection in the mouth because of the body’s reduced capacity to fight infection. According to The Gum Disease — Diabetes Project, gum disease causes “pockets” that are much deeper than the normal gap between tooth and gum. When this happens, you can no longer reach into the pocket with floss or a toothbrush, so it’s hard to get the germs out, although using a toothpick sometimes helps. That’s where professional help comes in. “Elimination of periodontal infection and reduction of periodontal inflammation in diabetic patients resulted in a significant short-term reduction in the concentration of glycosylated hemoglobin (HbA1c).”[17]

REFERENCES

1. Almadih A, Al-Zayer M, Dabel S, Alkhalaf A, Al Mayyad A, Bardisi W, et al. Orthodontic Treatment Consideration in Diabetic Patients. *J Clin Med Res.* 2018 ;10(2):77–81.
2. Bensch L, Braem M, Willems G. Orthodontic considerations in the diabetic patient [Internet]. Vol. 10, *Seminars in Orthodontics*. 2004. p. 252–8. Available from: <http://dx.doi.org/10.1053/j.sodo.2004.09.005>
3. Bensch L, Braem M, Van Acker K, Willems G. Orthodontic treatment considerations in patients with diabetes mellitus [Internet]. Vol. 123, *American Journal of Orthodontics and Dentofacial Orthopedics*. 2003. p. 74–8. Available from: <http://dx.doi.org/10.1067/mod.2003.53>
4. Bjork S, Kapur A, King H, Nair J, Ramachandran A. Global policy: aspects of diabetes in India. *Health Policy*. 2003 Oct;66(1):61–72.
5. Karunakar R, Anitha E. Orthodontic Management Of Medically Compromised Patients [Internet]. Vol. 1, *Annals And Essences Of Dentistry*. 2009. p. 1–11. Available from: <http://dx.doi.org/10.5368/aedj.2009.1.2.1-11.pdf>

International Journal of Innovative Research in Science, Engineering and Technology

(A High Impact Factor, Monthly, Peer Reviewed Journal)

Visit: www.ijirset.com

Vol. 8, Issue 8, August 2019

6. Straka M. Oral manifestations of diabetes mellitus and influences of periodontological treatment on diabetes mellitus. Bratisl Lek Listy. 2011;112(7):416–20.
7. Jha R, Kalyani P, Bavishi R. Oral Manifestations of Diabetes [Internet]. Vol. 2, Journal of Research in Medical and Dental Science. 2014. p. 6. Available from: <http://dx.doi.org/10.5455/jrmds.2014232>
8. Reichert C, Deschner J, Jäger A. Influence of Diabetes Mellitus on the Development and Treatment of Malocclusions – A Case Report with Literature Review [Internet]. Vol. 70, Journal of Orofacial Orthopedics / Fortschritte der Kieferorthopädie. 2009. p. 160–75. Available from: <http://dx.doi.org/10.1007/s00056-009-0819-9>
9. Lal S, Cheng B, Kaplan S, Softness B, Greenberg E, Goland RS, et al. Accelerated Tooth Eruption in Children With Diabetes Mellitus [Internet]. Vol. 121, PEDIATRICS. 2008. p. e1139–43. Available from: <http://dx.doi.org/10.1542/peds.2007-1486>
10. Friedlander AH, Friedlander IK, Yueh R, Littner MR. The prevalence of carotid atheromas seen on panoramic radiographs of patients with obstructive sleep apnea and their relation to risk factors for atherosclerosis [Internet]. Vol. 57, Journal of Oral and Maxillofacial Surgery. 1999. p. 516–21. Available from: [http://dx.doi.org/10.1016/s0278-2391\(99\)90065-4](http://dx.doi.org/10.1016/s0278-2391(99)90065-4)
11. Abbassy M, Watari I, Ono T. The Effect of Type 1 Diabetes Mellitus on the Craniofacial Complex [Internet]. Type 1 Diabetes Complications. 2011. Available from: <http://dx.doi.org/10.5772/24104>
12. Räkel A, Sheehy O, Rahme E, LeLorier J. Osteoporosis among patients with type 1 and type 2 diabetes. Diabetes Metab. 2008 Jun;34(3):193–205.
13. Lappin DF, Eapen B, Robertson D, Young J, Hodge PJ. Markers of bone destruction and formation and periodontitis in type 1 diabetes mellitus. J Clin Periodontol. 2009 Aug;36(8):634–41.
14. Mishima N, Sahara N, Shirakawa M, Ozawa H. Effect of streptozotocin-induced diabetes mellitus on alveolar bone deposition in the rat. Arch Oral Biol. 2002 Dec;47(12):843–9.
15. Rizvi SA, Sabrish S, Pai S, Pattabiraman V. Diabetes mellitus, A Dilemma in Orthodontics [Internet]. Vol. 2, Journal of Orthodontic Research. 2014. p. 113. Available from: <http://dx.doi.org/10.4103/2321-3825.140620>
16. Tong DC, Rothwell BR. Antibiotic prophylaxis in dentistry: a review and practice recommendations. J Am Dent Assoc. 2000 Mar;131(3):366–74.
17. Dowell S, Oates TW, Robinson M. Implant success in people with type 2 diabetes mellitus with varying glycemic control [Internet]. Vol. 138, The Journal of the American Dental Association. 2007. p. 355–61. Available from : <http://dx.doi.org/10.14219/jada.archive.2007.0168>