

**International Journal of Innovative Research in Science,
Engineering and Technology**

(A High Impact Factor, Monthly, Peer Reviewed Journal)

Visit: www.ijirset.com

Vol. 8, Issue 7, July 2019

Comparative Efficacy of Deep Skin Scrapings Test, Hair Pluck Method and Tape Impression Method Employed for Diagnosing Demodicosis in Dogs

Amithy S Nair¹, Umesh C. G.², Biju. P. Habeeb³, Vinu David. P⁴, Reghu Ravindran⁵

P.G. Student, Department of Veterinary Clinical Medicine, Ethics and Jurisprudence, KVASU, Kerala, India¹

Assistant Professor, Department of Veterinary Clinical Medicine, Ethics and Jurisprudence, KVASU, Kerala, India²

Assistant Professor, Department of Veterinary Clinical Medicine, Ethics and Jurisprudence, KVASU, Kerala, India³

Assistant Professor, Department of Veterinary Clinical Medicine, Ethics and Jurisprudence, KVASU, Kerala, India⁴

Assistant Professor, Department of Veterinary Parasitology, KVASU, Kerala, India⁵

ABSTRACT: The present study was undertaken to compare the three methods commonly used for the diagnosis of demodicosis in dogs presented in Teaching Veterinary Clinical Complex, College of Veterinary and animal sciences, Pookode, Wayanad district, Kerala, India. Total of 125 dogs were presented with clinical signs such as hairloss, erythema and skin lesions suggestive of demodicosis. Deep skin scrapings, tape impression smears and hair plucks were collected and subjected to microscopical examination under 10X and 40X magnification. A total of 26 cases were positive for *Demodex* mites. Sensitivity of different tests employed for diagnosing demodicosis in the present study was calculated as 96.15 per cent for deep skin scrapings, 76.92 per cent for hair pluck method and 15.38 per cent for tape impression smear. Sensitivity of tape impression smear method was 80 percent (4 out of 5) in generalised demodicosis.

KEYWORDS: Demodicosis, dogs, Kerala

I. INTRODUCTION

Dogs are prone to many systemic diseases of which skin diseases are very problematic and inflexible. Even though *Demodex* mite is a normal inhabitant of skin, any immunosuppressive conditions or genetic defects can lead to the proliferation of mites and expression of clinical signs. *Demodex canis* is said to be the main causative agent of canine demodicosis. Exact pathogenesis of canine demodicosis is unknown but Juvenile onset demodicosis is said to be a multifactorial disease, with genetics, nutrition, stress, and breed appearing to be contributing factors (Mueller, 2004). Canine demodicosis can be classified as either juvenile or adult in onset based on the age of the dog when the skin lesions first appear; both forms may be generalized or localized (Saridomichelakis *et al.* 1999). Local or diffuse alopecia, erythema, scale or crusts associated with papular or pustular dermatitis are the main clinical presentations of demodectic mange (Shipstone 2000). The diagnosis is based on detection of mites in deep skin scrapings. The present study was planned with the following objective.

- a. Comparison of three methods (deep skin scrapings, hair pluck method and tape impression smear method) for the diagnosis of canine demodicosis.

International Journal of Innovative Research in Science, Engineering and Technology

(A High Impact Factor, Monthly, Peer Reviewed Journal)

Visit: www.ijirset.com

Vol. 8, Issue 7, July 2019

II. RELATED WORK

Many research work have been done on the prevalence of canine demodicosis and clinical manifestations in different parts of the world. Comparison of hair pluck and tape impression methods was done by many researchers.

III. MATERIALS AND METHODS

Deep skin scrapings test

The deep skin scrapings test (DST) was performed as follows: A drop of mineral oil was placed either on the sterile blade used for scrapping or over the skin lesion to adhere more debris for preventing escape of mites. Area of skin to be scrapped was squeezed during and in between scrapings using thumb and index finger to extrude the mites from the deep follicles to the surface. Skin scraping was performed in the direction of hair growth, until capillary bleeding was observed (Shrestha *et al.*, 2015). The scrapings were taken from three or more sites in the case of generalized skin lesions. The skin scrapings were processed in 10% KOH (w/v) solution to remove skin debris and hair. Pellets of KOH marketed by Nice Chemicals, India were used for preparing 10% solution. The samples were placed in the test tube and 10% KOH solution was added until the level reached above the sample. Then the mixture was gently heated (near up to the boiling) with frequent shaking for about 5-10 minutes until all the debris were digested. The resultant solution was allowed to cool for some time and was centrifuged at 2000 rpm for 10 minutes. Supernatant was discarded, transferred the sediments to a slide and covered with a coverslip.

Hair pluck method (plate1a)

Hairs from skin lesion were plucked using hemostatic forceps in the direction of the hair growth and placed in a drop of liquid paraffin on a glass slide.

The deep skin scrapings, acetate tape impression smears and hair plucks were immediately examined under 10X and 40X magnification. The finding of one or more adult *Demodex* mites and/or its life stages like ova, larvae and nymph were considered positive

Tape impression smear method (plate 1b)

A transparent acetate tape strip of dimension 5 cm length and 2.5 cm width was placed on the lesion. Using thumb and index finger digital pressure was applied over the tape for dislodging the mites outwards the follicle. With pressure applying on the skin surface, the tape was removed and fixed on a glass slide (Pereira *et al.*, 2015).

IV. RESULTS AND DISCUSSION

The results of various laboratory tests used for diagnosing demodicosis in dogs under study were presented in **Table 1**. The microscopic examination of clinical samples was shown in **plate 2**.

Different diagnostic tests like deep skin scrapings, trichogram and tape impression smear in the present study group of 26 dogs yielded positive results in 25, 20, four respectively with sensitivity of 96.15 per cent per cent, 76.92 per cent and 15.38 per cent respectively. Sensitivity of tape impression smear method was 80 percent (4 out of 5) in generalised demodicosis. Deep skin scrapings test was found to be more sensitive in the present study. This is similar with the finding of Scott *et al.* (2001), who reported that Deep skin scraping is currently the main method used for the diagnosis

International Journal of Innovative Research in Science, Engineering and Technology

(A High Impact Factor, Monthly, Peer Reviewed Journal)

Visit: www.ijirset.com

Vol. 8, Issue 7, July 2019

of canine demodicosis and the method of choice for evaluation of cure of the patient. The higher efficacy of tape impression (80 per cent) for detecting *Demodex* mites in generalised forms in the present study is in accordance with findings of Cury *et al.* (2013) who reported that sensitivity of tape impression and hair pluck method (85 and 73 per cent respectively) was higher in generalised demodicosis. Hair pluck method may be used as a less traumatic alternative method for diagnosing demodicosis from sensitive areas of the body such as peri-oral, peri-ocular and interdigital space.

Table 1. Sensitivity of different diagnostic tests for demodicosis

Sl. No.	Diagnostic method	Positive	Tested	Sensitivity	Chi square value P value
1	Deep skin scrapings	25	26	96.15%	14.735 ^a P = 0.001
2	Hair pluck	20	26	76.92%	
3	Tape impression	4	26	15.38%	

P<0.01- Highly significant

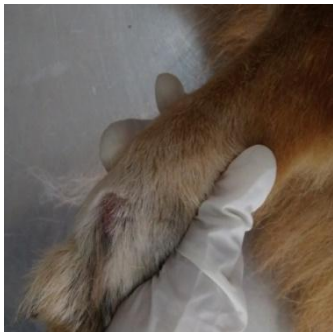

Plate 1b. hair pluck method

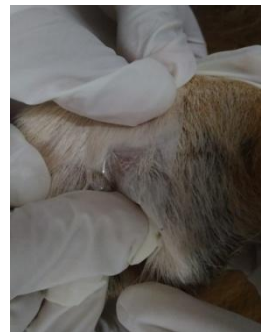
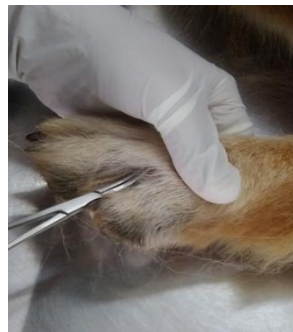
plate 1c. Tape impression smear

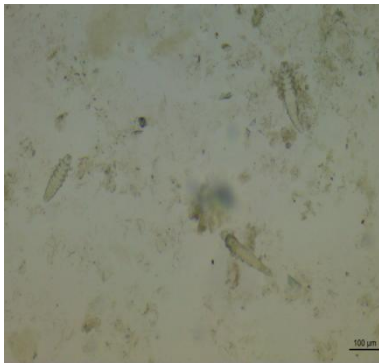
International Journal of Innovative Research in Science, Engineering and Technology

(A High Impact Factor, Monthly, Peer Reviewed Journal)

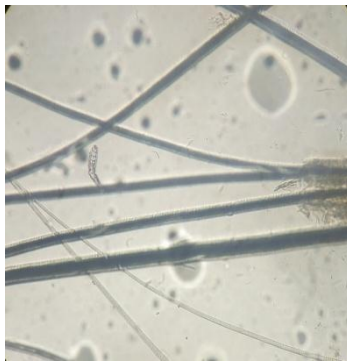Visit: www.ijirset.com

Vol. 8, Issue 7, July 2019

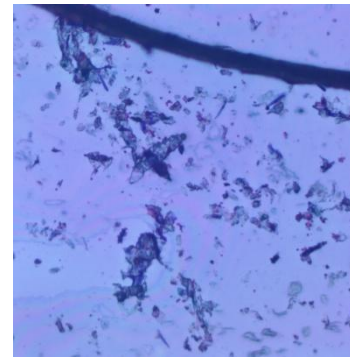
Plate 2. Microscopical examination of *Demodex* mites



Mites observed from deep skin scraping (under 10X magnification)



Mites observed from trichogram sample (under 10X magnification)



Mites observed from tape impression smear (under 10X magnification)

V. CONCLUSION

Among the three diagnostic methods deep skin scraping is found to be more sensitive. But procedural errors may occur, so always go for scrapings from different sites. Since hair pluck method and tape impression smear methods are less traumatic these methods can be used in sensitive areas such as peri-ocular, peri-oral and interdigital areas. Tape impression smear method is sensitive for generalised demodicosis. The combined use of three methods is always efficient than fully depending on one method.

ACKNOWLEDGEMENT

The authors would like to thank Kerala Veterinary and Animal Sciences University for providing financial support for the present research work.

REFERENCES

- 1) Arsenovic, M., Pezo, L., Vasic, N., Ciric, R., Stefanovic, M., "The main factors influencing canine demodicosis treatment outcome and determination of optimal therapy", *Parasitol. Res*, Vol.114, pp. 2415–2426, 2015.
- 2) Arunasri, S., Tirumala, Rao, D.S., Ameer, Hamza, P. and Satyanarayana., "Etiological, clinical and therapeutic studies on Canine Pyoderma", MVSc Thesis, Submitted to SVVU, Tirupati. 2008
- 3) Ballari, S., Balachandran, C., Titus, G. V. and Murali, M. B., "Pathology of canine demodicosis", *J. of Vet. Parasitol*, Vol. 23, pp. 179-182, 2009.
- 4) Chakraborty, S. and Pradhan, N. R., "Canine demodicosis and its herbal and nonherbal treatments", *Indian J.of Canine Practice*, Vol.7, pp.115, 2015.
- 5) Cury, G.M. M., Pereira, S.T., Botoni, L. S., Pereira, R. D., Telles, T. C., Ferreira, A. P. and Costa-Val, A. P., "Diagnosis of canine demodicosis: comparative study between hair plucking and adhesive tape tests", *Brazilian J. of Vet.Parasitol*, Vol 20, pp.137-139, 2013..
- 6) Elsheikha, H., Freeman, E., Madouasse, S. P. and Flynn, R., "Risk factors predisposing dogs to demodicosis: a retrospective study". *Veterinary Times*. Vol.40, pp.26, 2011.
- 7) Haleem, M. M. A., Salib, F. A. and Farag, H. S., "Evaluation of haematological parameters, biochemical Parameters and thyroxin level in dogs with generalized demodicosis", *Glob. Vet*, Vol.15, pp.133-136, 2015.
- 8) Harkirat, S., Jyoti, Haque, M., Singh, N.K. and Rath, S. S., "Prevalence of canine parasitic infections in and around Ludhiana, Punjab", *J. of Vet. Parasitol*, Vol.25, pp.179-180, 2011.

International Journal of Innovative Research in Science, Engineering and Technology

(A High Impact Factor, Monthly, Peer Reviewed Journal)

Visit: www.ijirset.com

Vol. 8, Issue 7, July 2019

- 9) Hill, P.B., Lo, A., Eden, C.A.N., Huntley, S., Morey, V., Ramsey, S., Richardson, C., Smith, D.J., Sutton, C., Taylor, M.D., Thorpe, E., Tidmarsh, R. and Williams, V., "Survey of the prevalence, diagnosis and treatment of dermatological conditions in small animals in general practice", *Vet. Rec.* Vol. **158**, pp.533-539, 2006.
- 10) Hillier, A. and Desch, C. E., Large-bodied Demodex mite infestation in 4 dogs. *J. of the Am.Vet.Med.Ass.* Vol. **220**, pp. 623-627, 2002.
- 11) Hnilica, K., *Small Animal Dermatology* (3rd Ed). Saunders St. Louis, Missouri, 576p.
- 12) Janus, A., Tresamol, P. V., Mercey, K. A., Habeeb, B. P. and Shameem, H., "A study on clinical and haematobiochemical parameters in canine demodicosis", *Indian j. of canine pract.* Vol. **6**, 2014
- 13) Mueller, R.S., "Treatment protocols for demodicosis: an evidence-based review", *Vet. Dermatol.* Vol. **15**, pp.75-89, 2004.
- 14) Nambi, A. P., Kavitha, S. and Srinivasan, S. R., "Evaluation of Effect of Oral Ivermectin Combined with Oral Antibiotic in the Treatment of Demodicosis in Dogs". *Intas Polivet.* Vol. **11**, pp. 69-73, 2010.
- 15) Nayak, D.C., Tripathy, B.S., Dey, C.P., Ray, K.S., Mohanty, N.D., Parida, S.G., Biswal, S., Das, M., "Prevalence of canine demodicosis in India (Orissa)", *Vet. Parasitol.* Vol. **73**, pp.347-352, 1997.
- 16) Pereira, A.V., Pereira, S. A., Gremiao, I. D. F., Campos, M. P. and Ferreira, A. M. R., "Comparison of acetate tape impression with squeezing versus skin scraping for the diagnosis of canine demodicosis". *Aust. Vet. J.* Vol. **90**, pp. 448-450, 2012.
- 17) Plant, J. D., Lund, E. M. and Yang, M., "A case-control study of the risk factors for canine juvenile - onset generalized demodicosis in the USA", *Vet. Dermatol.* Vol. **22**, pp.95-99, 2010.
- 18) Rajesh, K., Reddy, S.M and Swathi, B., "Canine demodicosis", *The pharma innovation*, Vol. **7**, pp. 548-550, 2018.
- 19) Sakina, A., Mandial, R. K. and Qazi, M., "Haematobiochemical changes in canine demodicosis", *Vetscan.* Vol. **7**, pp. 75-78, 2012.
- 20) Saridomichelakis, M.N., Koutinas, A., Papadogiannakis, E., Papazachariadou, M., Liapi, M. and Trakas, D., "Adult-onset demodicosis in two dogs due to *Demodex canis* and a short-tailed demodectic mite", *J. of Small Anim. Practice*, Vol. **40**, pp. 529-532, 1999.
- 21) Shrestha, D., Thapa, B., Rawal, G., Santosh, D. and Sharma, B., "Prevalence of demodectic mange in canines of Kathmandu valley having skin disorder and its associated risk factors", *IJASB*, Vol. **3**, pp. 459-463, 2015.
- 22) Shipstone, M., "Generalised demodicosis in dogs, clinical perspective", *Aust. Vet. J.* Vol. **78**, pp.240, 2000.
- 23) Singh, S. K., Dimri, U., Sharma, M. C., Swarup, D., Sharma, B., Pandey, H. O. and Kumari, P., "The role of apoptosis in immunosuppression of dogs with demodicosis", *Vet. Immunol. and Immunopathology*, Vol. **144**, pp.487- 492, 2011.
- 24) Soodan, J.S., AnishYadav. and Khajuria, J. K., "comparative efficacy of some acaricides against demodicosis in dogs", *Intas polivet*, Vol. **6**, pp. 335-337, 2005.
- 25) Yattoo, M. I., Jhambh, R., Deepa, P. M., Kumar, P. and Dimri, U., "Advances in therapeutic management of complicated demodicosis in canines", *J. of Adv.in Parasitol.* Vol. **1**, pp. 6 - 8, 2014.