

Abnormality Classification of Diabetic Macular EDEMA in Retinal Images

Angurajsiva. J¹, Mrs. S. Vasanthi²

PG Scholar, K. S. Rangasamy College of Technology, Tiruchengode, Namakkal-637 215 ,Tamilnadu, India¹

Associate Professor, K. S. Rangasamy College of Technology, Tiruchengode, Namakkal-637 215, Tamilnadu, India²

Abstract --- Diabetic Macular Edema disease leads to vision loss problem in Diabetic patients. Early detection of Macular Edema in diabetic patients pave a path for prevention from blindness. Diabetic Macular Edema (DME) occurs when blood vessels in the retina of patients with diabetes begin to leak into the macula region of eye. These leakages cause the macula to thicken and swell, progressively leads to vision loss. The automatic detection of Diabetic Macular Edema and classification of DME severity is done in this paper. The Hard Exudates (HE) presence in macula region is detected and the features are extracted. The extracted features are inputised to Adaptive Neuro Fuzzy Inference System (ANFIS) to classify the images as normal and the abnormal image severity levels as mild, moderate and severe.

Index terms --- Diabetic Macular Edema (DME), Neuro-Fuzzy, Hard Exudates, Severity level.

I. INTRODUCTION

Recent years, Diabetes become a common disease in the world. Diabetes affects the retina of the eye and leads to Diabetic Retinopathy, which cause blindness. Diabetic Macular Edema comes under Diabetic Retinopathy category. Diabetic Retinopathy (DR), is a disease causes damage to the retina of human eye, which is caused by complications of diabetes. DR commonly leads to vision loss. It is an important disease which affects nearly 80% of the patients who have diabetes nearly 10 years or more. Upon undergoing the research on this Diabetic Retinopathy diseases, the statistics shows that at least 90% of the disease is reduced by proper initial treatment and consult the ophthalmologist at an early stage itself. If a person has diabetes for longer period, the chances of developing diabetic retinopathy is higher.

Diabetic Retinopathy, a frequent diabetic retinal diseases are caused due to the blood vessels in the retina get changes from its original shape. At the center part of the retina there is a very small area called as macula. The macula region is responsible for the pinpoint vision, allowing the human to view or recognize something. The retinal surrounding part is called the peripheral retina, which is responsible for side or peripheral vision. Diabetic Retinopathy generally affects both the human eyes.

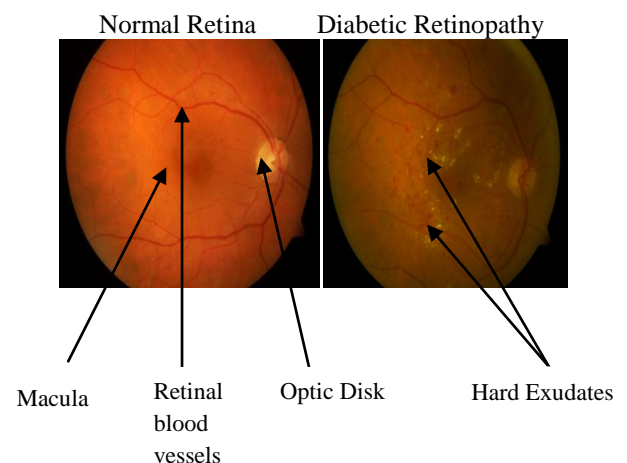


Fig. 1 Normal Retinal image and DR image

Examination has been carried out either manually on examining stereoscopy or Optical Computed Tomography images or by detection of Hard Exudates (HE) in the retinal region of human eye. The severity of the disease is evaluated by the Hard Exudates presence. If HE present near the macula means the severity is moderate and if HE present inside the macula region means the severity is high. At the initial stage of this disease, the ability of vision starts to decrease. Earlier stage itself patients should concern their problems in vision with the

ophthalmologist. Then the ophthalmologist proceeds their screening tests to know the level of severity. This paper deals with the automatic detection of DME and classification of DME severity level using Neuro-Fuzzy logic.

II. RELATED WORK

Macular edema is an advance stage of diabetic retinopathy which affects central vision of diabetes patients. The main cause of edema is the appearance of exudates near or on macular region in human retina. An automated system for early detection of macular edema should identify all possible exudates present on the surface of retina. In [1] present a method for the identification of exudates in color retinal images which will help in building a computer aided diagnostic system for macular edema. The proposed system consists of three stages: candidate exudate detection, feature extraction and classification. Exudates also known as bright lesions, appear as bright spots and patches in fundus image with highest contrast in the green plane of the color image [2]. An automated system for detection of exudates should enhance the contrast of bright regions with smoothing of dark regions. For exudate detection, morphological closing is used to smooth dark regions such as haemorrhages and blood vessels. The aim is to increase the lesions contrast by $w \times w$ sliding window for easy detection in image enhancement[3].

Gabor filter bank is used for detection of all possible bright regions. They are appropriate for texture representation and discrimination [4]. The regions segmented by thresholding of filter bank based enhanced image also contain OD region and pixels due to their similarity with exudates [5]. For accurate detection exudates, these false and spurious pixels should be removed before the classification stage. The proposed system locates and segments optic disc using image averaging and Hough transformation respectively.

The exudates shape and size will vary with the different retinopathy stages. The Fundus image is first preprocessed to standardize its size to 576x720. For the detection of exudates, initially extract the green channel of RGB color image. Structuring elements (SEs) were used. A morphological closing operation was performed using an octagon-shaped SE. This results in a good contrast image between the exudates and the background [6]. Column wise neighborhood operation was performed to remove the unwanted background artifacts, leaving only the exudates and the optical disc.

Thresholding is useful to remove unnecessary details from an image to concentrate on essentials [7]. A novel method to automatically detect HEs in color retinal images is proposed [8]. Hard Exudates candidates regions are extracted by histogram segmentation combined with morphological reconstruction. The significant features for each candidate region are defined. A supervised support vector machine (SVM) is finally trained based on these features to classify the candidate regions for HEs.

DR is one of the main causes of vision loss and its prevalence keeps rising [9]. Hard Exudates (HEs) have been known as the specific marker of DR [10]. Thus, the clinical examination of HEs is essential to the early diagnosis and treatment of DR. Thresholding-based techniques focus on a global or adaptive grey level analysis [11], but the automatic selection of proper threshold is difficult due to the uneven illumination of the image. Region growing-based techniques segment retinal images based on the spatial contiguity and illumination homogeneity of the HEs [12] which are computationally expensive. To enhance the computational efficiency, the edge detection is employed to limit the size of regions in [13]. Morphology-based techniques apply greyscale morphological operators to remove uninterested structures (such as vessels) and then identify HEs effectively [14, 15]. Classification based techniques such as clustering algorithms [16], supervised approaches [17], statistical classification [18] and neural network [19, 20] attempt to extract different features (illumination, color, contrast, size etc.) and then use a classifier to classify HEs.

An automatic method to detect various macula pathologies is proposed [21]. Exudates detection algorithm is proposed [22] which is based on the combination of active contours obtained for the image after different preprocessing algorithms. In order to classify the candidate regions into Exudate or non- Exudate classes [23], a set of significant features was extracted from each region. Focused on those characteristics that help ophthalmologists to visually distinguish Exudates.

The automated solutions can be categorized as local schemes and global schemes. Local schemes performs localization of HE clusters. Given the relatively high contrast between the HE and retinal structures (except optic disc), the most common approach has been to process green channel of the color fundus image and thresholding (fixed or adaptive/dynamic) the intensity histogram [23]. Background suppression is another approach that has been used for finding HE candidates [24]. Global schemes are used for detecting the presence/absence of HE in images. Features such as visual word/group using a dictionary have been used to represent color fundus images to

help classify them as normal or abnormal [25]. The statistical features like area, mean, standard deviation, entropy etc are extracted using the candidate extractor algorithm [26].

III. METHODOLOGY

In this work DME is detected by Hard Exudates (HE) presence. Then the classification of color fundus images as normal or abnormal and in the abnormal image severity level as mild, moderate or severe is done by Neuro-Fuzzy logic. The Flowchart of the proposed methodology is shown in Fig. 2.

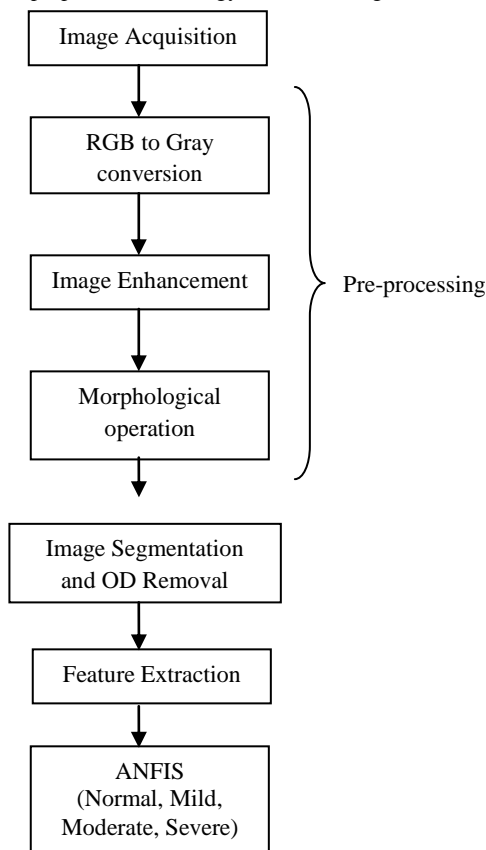


Fig. 2 Flowchart of Proposed Methodology

A. DATA ACQUISITION AND PRE-PROCESSING

Diabetic Macular Edema is detected by the Hard Exudates presence. In this paper initially the color fundus images are acquired then the preprocessing steps includes grayscale conversion from RGB image, Image enhancement is done by row interpolation and column interpolation, then the fundus images are standardised to a size 576 x 720 and the morphological operation image closing is performed. Since the Optic Disk shares the brightness characteristics of HE, it should be masked. Image is

segmented and the Optic Disk region is detected, masked and removed from the image.

B. FEATURE EXTRACTION

The features are to be extracted from the color fundus images for classification purpose. Gray level Co-occurrence Matrix (GLCM) is created and its parameters are evaluated for classification which are considered as features. Area is also included as feature. The GLCM parameters are :

1. Contrast - It is a measurement of intensity contrast between a pixel and its neighbourhood pixels in the whole image. The range of contrast feature is :
Range = $(0 \text{ (size (GLCM, 1) - 1)}^2)$

$$\text{Contrast} = \sum_{i,j} |i - j|^2 P(i, j) \quad (1)$$

2. Correlation – It is a measure of how a pixel is correlated to its neighbourhood pixel in whole image. Its range is from -1 to +1. Correlation is NaN for a constant image. It is +1 for perfect positively correlated image and -1 for perfect negatively correlated image.

$$\text{Correlation} = \sum_{i,j} ((i - \mu_i)(j - \mu_j)P(i - j)) / (\sigma_i \sigma_j) \quad (2)$$

3. Energy – It is the sum of squared elements in GLCM. It ranges from 0 to 1. For constant image, energy value is 1.

$$\text{Energy} = \sum_{i,j} P(i,j)^2 \quad (3)$$

4. Homogeneity – The closeness measurement of the elements distribution in GLCM to GLCM diagonal. It ranges from 0 to 1. For diagonal GLCM Homogeneity value is 1.

$$\text{Homogeneity} = \sum_{i,j} P(i, j) / (1 + |i - j|) \quad (4)$$

C. CLASSIFICATION

Dataset is formed by using The features such as contrast, correlation, energy, homogeneity and various stages of abnormalities are classified. ANFIS is used to classify the retinal images as normal, mild, moderate and severe depending on their severity. Adaptive Neuro Fuzzy Inference System (ANFIS) is one type of neural network which is based on Takagi–Sugeno fuzzy inference system [27], [28]. The FIS is generated using grid partitioning. Inference system of

ANFIS corresponds to a set of fuzzy IF–THEN rules. These rules have learning capability to approximate nonlinear functions. ANFIS is an adaptive network. An adaptive network is a network of nodes and directional links. This network is called adaptive because output node is affected by parameters of some nodes in the network. These networks are also learns the relationship between inputs and outputs. Hybrid learning is used as a optimization method to train the FIS which combines the pattern and batch learning rules. Adaptive Neural Fuzzy Inference System approach learns the rules and membership functions from data.

ANFIS structure depends on the training set and testing set. In this paper training and testing set are formed from the features like area, contrast, correlation, energy, and homogeneity are given as input to ANFIS. To train the network 89 retinal images were taken then the system is loaded with the statistical features, which are area, contrast, correlation, energy and homogeneity of these retinal images from the workspace or from file. The next step is to load the test data from the workspace for 89 retinal images.

IV RESULTS

A. INPUT IMAGE

The various input retinal images are acquired and subjected for further classification.

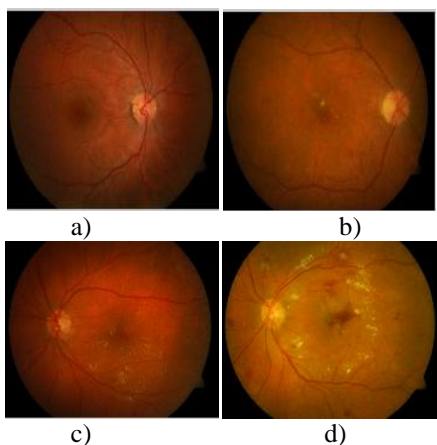


Fig. 3 Input Color Fundus Images

B. RGB TO GRAY CONVERSION

The input Color Fundus images are converted to grayscale image for the proceeding process.

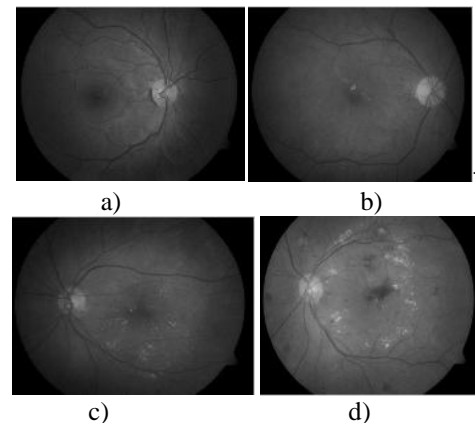


Fig. 4 RGB to Gray conversion

C. IMAGE ENHANCEMENT

The converted grayscale image is enhanced i.e., the brightness of the whole image is increased for the clear visibility of the internal parts of the retinal image.

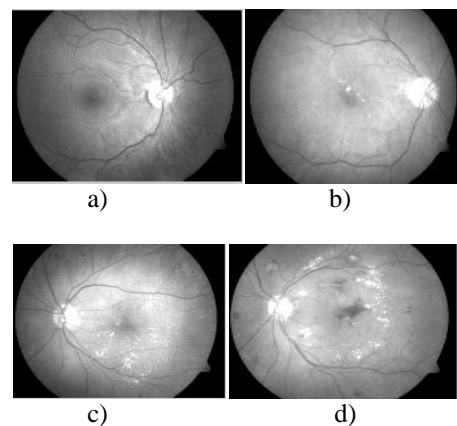


Fig. 5 Image Enhancement

D. MORPHOLOGICAL OPERATION

The morphological closing is performed in the enhanced retinal image.

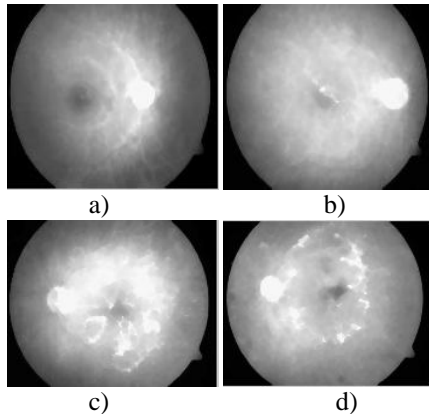


Fig. 6 Morphological operation

E. SEGMENTED IMAGE

The high intensity regions are segmented out from the retinal images.

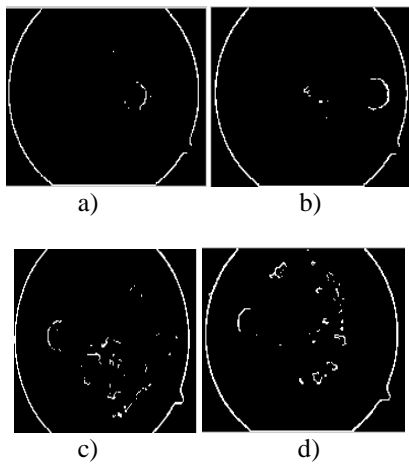


Fig. 7 Segmented image

F. REMOVAL OF OD REGION

Since OD region shares the same brightness characteristics as like the Hard Exudates, hence the OD region is removed.





Fig. 7 Removal of OD region

G. FEATURE EXTRACTION

The different features for the input images are extracted at normal, mild, moderate and severe stages and the values are tabulated in Table. 1.

Feature	Normal	Mild	Moderate	Severe
Area	30	452	2473	3324
Contrast	0.023	0.019	0.019	0.019
Correlation	0.980	0.985	0.982	0.991
Energy	0.345	0.361	0.348	0.333
Homogeneity	0.988	0.990	0.990	0.990

Table. 1 Feature values for input images

H. CLASSIFICATION

The extracted features are given as input to ANFIS which classifies the image as normal, mild, moderate and severe based upon the features.

V CONCLUSION

The proposed methodology involves DME detection and severity classification in retinal images. The important contribution of this work includes: 1) Significant representation for preprocessing stages and the removal of OD region. 2) Adaptive Neuro Fuzzy Inference System (ANFIS) is used for detecting the severity of DME in retinal images. The image characteristics are assessed for the classification of the normal and the severity level of the abnormality in the macular region of human eye. The proposed technique helps for automatic detection and abnormality classification of DME in reliable manner.

REFERENCES

1. Umer Aftab and M. Usman Akram "Automated Identification of Exudates for Detection of Macular Edema" IEEE Cairo International Biomedical Engineering Conference, December, 2012.
2. M. U. Akram, A. Tariq, M. A. Anjum, M. Y. Javed, "Automated Detection of Exudates in Colored Retinal Images for Diagnosis of Diabetic Retinopathy", OSA Journal of Applied Optics, vol. 51, No. 20, pp. 4858-4866, 2012.
3. Alireza O., B. Shadgar and R. Markham, "A Computational-Intelligence- Based Approach for Detection of Exudates in Diabetic Retinopathy Images", IEEE Trans on Information Tech in Biomedicine, vol. 13, No.4, 535-545, 2009.
4. J. Sung, S. Y. Bang, S. Choi, "A Bayesian Network Classifier and Hierarchical Gabor Features for Handwritten Numeral Recognition", Pattern Recognition Letters, 2005.
5. R. C. Gonzalez and R. E. Woods, "Digital image processing", Prentice hall. second edition, 2002.
6. Eman M.Shahin, Taha E. Taha, W. Al-Nuaimy, S. El Rabaie, Osama F.Zahran and Fathi E. Abd El-Samie, "Automated detection of Diabetic Retinopathy in Blurred digital fundus images" IEEE conference, 2012.
7. A. McAndrew, "Introduction to Digital Image Processing With Matlab", 528 pages, Published April 7th 2004 by Course Technology.
8. Xiang chen, Wei bu, Xiangqian wu, Baisheng dai, Yan teng, "A novel method for Hard Exudates detection in color retinal images", Proceedings of the 2012 International Conference on Machine Learning and Cybernetics, Xian, 15-17 July, 2012.
9. Olson JA, Strachan PM, Hipwell JH, Goatman KA, McHardy KC, Forrester JV, and Sharp PF, "A comparative evaluation of digital imaging, retinal photography and optometrist examination in screening for diabetic retinopathy," Diabetic Medicine, vol. 20, no. 7, pp. 528-534, 2003.
10. S. Bjorvig, M.A Johansen, and K. Fossen, "An economic analysis of screening for diabetic retinopathy", Journal of Telemedicine and Telecare, vol. 8, no. 1, pp. 32-35, 2002.
11. Sanchez CI, Garda M, Mayo A, Lopez MI, and Homero R, "Retinal image analysis based on mixture models to detect hard exudates," Medical Image Analysis, vol. 13, no. 4, pp. 650-658, 2009.
12. Sinthanayothin C, Boyce JF, Williamson TH, Cook HL, Mensah E, Lal S, and Usher D, "Automated detection of diabetic retinopathy on digital fundus images," Diabetic Medicine, vol. 19, no. 2, pp. 105-112, 2002.
13. H. Li and O. Chutatape, "Automated feature extraction in color retinal images by a model based approach," IEEE transactions on Bio-medical Engineering, vol. 51, no. 2, pp. 246-254, 2004.
14. Walter T, Klein JC, Massin P, and Erginay A, "A contribution of image processing to the diagnosis of diabetic retinopathy-detection of exudates in color fundus images of the human retina," IEEE Transactions on Medical Imaging, vol. 21, no. 10, pp. 1236-1243, 2002.
15. D. Welfer, I. Scharcanski, and D.R. Marinho, "A coarse-to-fine strategy for automatically detecting exudates in color eye fundus images," Computerized Medical Imaging and Graphics, vol. 34, no. 3, pp. 228-235, 2010.
16. W. Hsu, P.M.D.S. Pallawala, Mong Li Lee, and KahGuan Au Eong, "The role of domain knowledge in the detection of retinal hard exudates," in IEEE Conference on Computer Vision and Pattern Recognition, 2000. Proceedings. IEEE, 2001, vol. 2, pp. II-246.
17. Niemeijer M, van Ginneken B, Russell SR, SuttorpSchulten MS, and Abramoff MD., "Automated detection and differentiation of drusen, exudates, and cottonwool spots in digital color fundus photographs for diabetic retinopathy diagnosis," Investigative Ophthalmology and Visual Science, 2007.
18. K.G. Goh, "Adris: an automatic diabetic retinal image screening system," Studies in Fuzziness and Soft Computing, vol. 60, pp. 181-210, 2001.
19. Mana Garda, Clara I. Sanchez, Maria I. Lopez, Daniel Abcisolo, and Roberto Homero, "Neural network based detection of hard exudates in retinal images," Computer Methods and Programs in Biomedicine, vol. 93, no. 1, pp. 9-19, 2009.
20. X. Zhang and O. Chutatape, "Top-down and bottomup strategies in lesion detection of background diabetic retinopathy" in IEEE Conference on Computer Vision and Pattern Recognition, 2000. Proceedings. IEEE, 2005, vol. 2, pp. 422-428.
21. Carla Agurto, Honggang Yu, Victor Murray, Marios S. Pattichis, Simon Barriga, Peter Soliz, "Detection of Hard Exudates and Red lesions in the macula using multiscale approach", IEEE, 2012.
22. Maria Garcia, Carmen Valverde, Maria I. Lopez, Jesus Poza and Roberto Hornero "Comparison of Logistic Regression and Neural Network Classifiers in the Detection of Hard Exudates in Retinal Images" 35th Annual International Conference of the IEEE EMBS Osaka, Japan, 3 - 7 July, 2013.
23. K.Sai Deepak and Jayanthi Sivaswamy, "Automatic Assessment of Macular Edema From Color Retinal Images" IEEE Transactions on Medical Imaging, Vol. 31, no.3, March 2012.
24. W.Huan, H.Wynne, and L.M Li, "Effective Detection of Retinal Exudates In Fundus Images", in Proc. 2nd Int. Conf. Biomed. Eng. Informat., October 2009, pp.1-5.
25. S.Ravishankar, A.Jain, and A.Mittal, "Automated Feature Extraction For Early Detection of Diabetic Retinopathy In Fundus Images," in IEEE Conf. Comput. Vis. Pattern Recognit., June 2009, pp. 210-217.
26. T.Yamuna, S.Maheswari, "Detection of abnormalities in retinal images", IEEE International Conference on Emerging Trends in Computing, Communication and Nanotechnology, 2013.
27. Anitha et al "Self organizing neural network based pathology classification in retinal images" IEEE world congress on natural & biologically inspired computing, pp. 1457-1462, Dec 2009.
28. Inan Guler et al "Adaptive neuro-fuzzy inference system for classification of EEG signals using wavelet coefficients" Journal of Neuroscience Methods-ELSEVIER, NSM-3945, vol.148, Issue 2, PP. 113-121, oct 2005.