

Performance Evaluation of Different Methods for Detection of Hemorrhage Using Fundus Images

Mulla R.M¹, Chavan M.S²

P.G. Student, Department of Electronics & Tele-communication Engineering, KIT Engineering College, Kolhapur,
India¹

Professor, Department of Electronics Engineering, KIT Engineering College, Kolhapur, India²

ABSTRACT: Image processing of a fundus image is performed for the early recognition of diabetic retinopathy. Diabetic retinopathy classified in two stages. First is non-proliferative which includes microaneurism and when blood vessels are leak and it comes into proliferative stage which is called hemorrhage. In this paper I discussed about detection of hemorrhage in diabetic retinopathy. extraction of hemorrhages using template matching with templates of various shapes has not been reported. Microaneurism are early sign of diabetic retinopathy Detection of hemorrhage may help the clinician in the diagnosis of diabetic retinopathy and might be a useful tool for early detection of diabetic retinopathy progression especially in the telemedicine. Diabetic retinopathy is a serious complication of diabetes mellitus and a major cause of blindness worldwide. Signs of diabetic retinopathy include red lesions such as micro aneurysms (MA), intraregional hemorrhages, and bright lesions, such as exudates and cotton wool spots. So early detection and proper treatment can prevent our eyes from blindness. In this paper I discussed hybrid method and brightness correction method for detection of hemorrhage in diabetic retinopathy. There was using various shape of template for detection of hemorrhage. Second method I applied in this study it was brightness correction and clahe method for detection. For recognize exact shape of hemorrhage region growing segmentation was used. Diabetic retinopathy is the most common cause of blindness in the working population of the United States. Early diagnosis and timely treatment have been preventing visual loss and blindness in patients with diabetes.

KEYWORDS: Diabetic retinopathy, Hemorrhage, Fundus image, Detection, Template

I. INTRODUCTION

Diabetes occurs when the pancreas fails to secrete enough insulin, slowly affecting the retina of the human eye. As it progresses, the vision of a patient starts deteriorating, leading to diabetic retinopathy. For the analysis of retinal images fundus images taken from fundus camera. The objectives of this study (i) detect blood vessel, (ii) identify hemorrhages and (iii) classify different stages of diabetic retinopathy into normal, moderate and severe. .classification of different stages of diabetic retinopathy may help us to identify the level of DR.so proper treatment which was suitable for this level of DR take by using of this classification. Taking treatment on this diabetic retinopathy regular eye check up was needed and gives the regular eye examination. The preliminary signs of diabetic retinopathy include micro aneurysms, hemorrhages and exudates. Early diagnosis and timely treatment can prevent vision loss in patients with long term diabetes .Diabetic retinopathy is retinopathy (damage of retina) in patients with long term diabetes, which leads to blindness There are two types of diabetic retinopathy namely proliferative and non proliferative diabetic retinopathy. Non proliferative diabetic retinopathy is the first stage of diabetic retinopathy. Micro aneurysms appear in this stage. The blood vessels become blocked and leads to retinal hemorrhages. As the disease progresses, severe non_proliferative diabetic retinopathy enters an advanced, or proliferate. [5] New blood vessels grow along the retina and vitreous humour that fills the inside of the eye. Later on these vessels bleed and destroy the retina. Fundus image analysis may help doctors for effective treatment on this disease. Diabetic retinopathy is a progressive disease and is broadly classify into two stages i.e. Non proliferative diabetic retinopathy (NPDR) and proliferative diabetic retinopathy (PDR) [5] A number

International Journal of Innovative Research in Science, Engineering and Technology

(An ISO 3297: 2007 Certified Organization)

Vol. 3, Issue 9, September 2014

of studies have shown that DR is one of the major causes of blindness in industrialized countries. Computer aided systems can help in timely and accurate detection of DR which can prevent complete blindness caused by DR. Digital fundus images of retina which are used for automated detection of DR contain blood vessels, optic disc, macula and fovea as main components.

II. RELATED WORK

A. Background of work

Diabetic retinopathy is major health issue in worldwide. Recent survey shows that four million people suffer from this disease. It was caused by low level of insulin in blood vessels. So timely treatments and giving time to time examination of retina can prevent diabetic patients from damage of retina. There are two types of sign which shown in patient one was dark lesion which includes hemorrhage and microaneurysms and second was bright lesion which include exudates and cotton wool spots. This paper focuses on the detection of haemorrhages in diabetic retinopathy because the hemorrhage is one important diagnostic criterion to determine the severity of diabetic retinopathy. Currently, the diagnosis of DR is made manually by an ophthalmologist who detects and calculates the hemorrhage size. Automating the diagnosis of DR will help in managing DR more efficiently and accurately. Jang pyo Bae et.al has presented that extraction of haemorrhages using template matching with templates of various shapes. He applied hue saturation value brightness correction and contrast-limited adaptive histogram equalization to fundus images. Result of his research may help the clinician in the diagnosis of diabetic retinopathy and might be a useful tool for early detection of diabetic retinopathy progression especially in the telemedicine.[1]Giri babu kande et.al has presented an efficient approach for automatic detection of red lesions in fundus image based on pixel classification & mathematical morphology is proposed. [2]Yuji Hatanka et.al has presented new method for detecting hemorrhage which may effectively improve the performance of our computer-aided diagnosis system for haemorrhages. It has improved automated hemorrhage detection method to help diagnose diabetic retinopathy. He purposes a new method in which a brightness of the fundus image was changed by the nonlinear curve with brightness values of the hue saturation value (HSV) space. [3]Alan D.fleming et.al has presented that automatic methods for MA detection and shows how image contrast normalization can improve the ability to distinguish between MAs and other dots that occur on the retina. Various methods for contrast normalization are compared. Dots within vessels are handled successfully using a local vessel detection technique. Results are presented for detection of individual MAs and for detection of images containing MA.[4]R.Vidyasari et.al has presented that there are two levels of diabetic retinopathy which are nonproliferative diabetic retinopathy (NPDR) and proliferative diabetic retinopathy (PDR).The presence of micro aneurysms in the eye is one of the early signs of diabetic retinopathy. Automated detection of micro aneurysms in digital colour fundus photographs is developed to help ophthalmologist to detect the emergence of its early symptoms and determine the next action step for the patient. They have developed micro aneurysms filter algorithm with the concept of vessel enhancement in order to extract the structure of micro aneurysms in medical imagery, especially in the retinal image. [5].

B.Problem Definition

Diabetic retinopathy is a serious complication of diabetes mellitus and a major cause of blindness worldwide. Diabetic retinopathy (DR) is a progressive eye disease cause due to increase of insulin in blood and can cause blindness if not detected timely. Diabetes occurs when the pancreas fails to secrete enough insulin, slowly affecting the retina of the human eye. [1]As it progresses, the vision of a patient loss, leading to diabetic retinopathy.DR caused by increased level of insulin level in blood vessels. So blood vessels may leak and broken and bleed was comes into retina it called as hemorrhage. Detection of hemorrhages in diabetic retinopathy is one of the important diagnostic criteria to determine the severity of diabetic retinopathy. Therefore The detection of hemorrhage in digital color fundus images it is a critically important to protect the eyes from blindness.

C.Objectives of Work

To accomplish detection of diabetes retinopathy number of methods have been published in the past but none of these was compared with each other on the same data. After classifying the well known methods of detection hemorrhage candidate will be extracted. The preliminary signs of diabetic retinopathy include micro aneurysms, hemorrhages. Early diagnosis and timely treatment can prevent vision loss in patients with long term diabetes .Diabetic retinopathy is

International Journal of Innovative Research in Science, Engineering and Technology

(An ISO 3297: 2007 Certified Organization)

Vol. 3, Issue 9, September 2014

retinopathy (damage of retina) in patients with long term diabetes, which leads to blindness. Considering the vast scope for the research in this area the following objective are defined for the proposed work.

- 1) Theoretical study of methods of detection of hemorrhage and diabetes retinopathy.
- 2) Collection of fundus Images (Developing data base)
- 3) To Study & analysis of the following methods.
 - I. Hybrid method.
 - II. Brightness correction method.
- 4) Performance Evaluation of above methods
- 5) Select the method which gives best result for hemorrhages detection from above.
- 6) To study classification of different stages of diabetic retinopathy.
- 7) Based on detection of hemorrhage classify different stages of diabetic retinopathy as normal, moderate and non-proliferative diabetic retinopathy (NPDR)

III. PROPOSED METHODOLOGY

1. Study of methods for detection of hemorrhage & diabetic retinopathy.
2. Collection of more than 100 fundus Images as database.
3. Study and analysis of hybrid and brightness correction method for detection of hemorrhage in diabetic retinopathy.
4. Apply both methods on fundus images.
5. Performance evaluation of both methods.
6. Study of both methods.
7. Based on result of comparison select appropriate method which give best result for detection of hemorrhage in diabetic retinopathy
8. To study the classification of different stages in diabetic retinopathy.
9. Based on detection of hemorrhage classify different stages of diabetic retinopathy as normal, moderate and non-proliferative diabetic retinopathy (NPDR)

IV. HYBRID METHOD

A. Introduction

Image processing on fundus images are used for detection of diabetic retinopathy. In this method there is used various shapes of template for detection of hemorrhage. But one template could not cover the entire hemorrhage so various size and shapes of template were used. Contrast limited adaptive histogram algorithm used for proper detection of hemorrhage. For getting exact shape of template region growing segmentation with local threshold were used in this study.

B. Flowchart of detecting hemorrhage

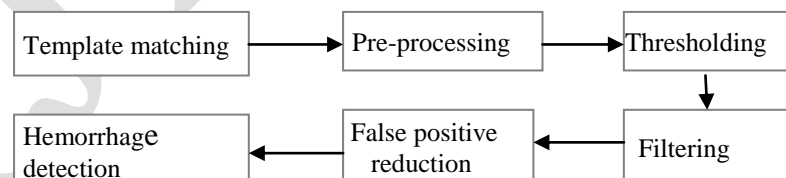


Figure 1: Flow Diagram for Hybrid Method [1]

C. Preprocessing

RGB image is combination of red, green and blue channel. Green channel represent red structure well and it was better contrasted than other channel. Red and blue channel wear less contrasted and noisy and they provide less information so green channel used for preprocessing. The main objective of preprocessing one is making the brightness of image uniform and second was to enhance the contrast between hemorrhage and background.

International Journal of Innovative Research in Science, Engineering and Technology

(An ISO 3297: 2007 Certified Organization)

Vol. 3, Issue 9, September 2014

D. Contrast-limited adaptive histogram equalization

To enhancing the contrast of image contrast limited adaptive histogram technique was used. The shape of a photograph is rectangular. However, the shape of an eye is rounded because the rectangular picture contains the round eye; in the fundus image, the dark outside region which surrounds an eye appears. [1] In general histogram equalization, the pixel of dark outside region is added the histogram, so values of pixels near this dark outside region were lower than the expected ones. CLAHE operates on small regions, called tiles, while the general algorithm works on the entire image. As the effect of extremely dark and bright regions is restricted to the local tile, a uniform image can be obtained.

E. Template matching

For the detection of hemorrhage candidate template matching technique used. one template could not cover the hemorrhage size. so set of different size of template used for detection of gathered hemorrhage. The shape of template is defined as the radius of the circle (r) and the outside width (a) as shown in Figure. The greater the radius of the circle, the larger the detected hemorrhages are. The longer the outside width of the template, the more background is included. Therefore, the independent circular hemorrhages could be easily detected but the gathered hemorrhages can be missed. In contrast, the short outside width makes it easy to detect the gathered hemorrhage. [1]

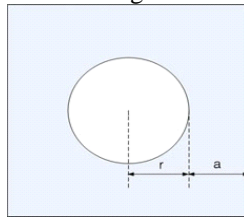


Figure 2: Template Matching [1]

F. Region growing segmentation

A hemorrhage candidate after template matching has only the information of the center point and the presumed size and lacks information of the exact shape which can be recovered using region growing segmentation. The goal of Image Segmentation is to find regions that represent objects or meaningful parts of objects. Major problems of image segmentation are result of noise in the image the main goal of segmentation is to partition an image into regions. Some segmentation methods such as thresholding achieve this goal by looking for the boundaries between regions based on discontinuities in grayscale or color properties.

G. Region growing segmentation using the local threshold

Thresholding is the simplest non-contextual segmentation technique. With a single threshold, it transforms a grayscale or color image into a binary image considered as a binary region map. Thresholding is the simplest method of image segmentation from a grayscale image; thresholding can be used to create binary images.

H. False positive reduction

Wrongly detected hemorrhage is called FP. to eliminate this area feature used twice. This eliminates small spots selected from template matching, and candidates whose sizes are below the area threshold were excluded. After region growing recovers the exact shape of the hemorrhage, thresholds of the area of hemorrhage is used to remove the FPs. The structure of the fundus image can give us wide information about the hemorrhage detection. To classify each of candidate objects as either a red lesion or non-red lesion, six filters are used. First, we used the shape, size, and compactness of the hemorrhages as first set of filters. The second set of filters used was the 5×5 kernel value and foveal filter. Next, we used 5 and 6 filters. Since the mean intensity under kernel is calculated on the reference image, the second filter needs the reference image. [1]

V. BRIGHTNESS CORRECTION METHOD

A. Introduction

This method is used to improve our automated hemorrhage detection method to help diagnose diabetic retinopathy. In this method nonlinear curve with brightness values of the hue saturation value (HSV) space. After that, the hemorrhage candidates were detected. Finally, false positives were removed by using a fovea filter.

DOI: 10.15680/IJIRSET.2014.0310027

International Journal of Innovative Research in Science, Engineering and Technology

(An ISO 3297: 2007 Certified Organization)

Vol. 3, Issue 9, September 2014

B. Digitization

Digitalization is the process in which manual text; records are converted into digital form. In which analog signal is converted into digital signal. It was also called digital representation, digital form or object. In which digital fundus images are captured by digital fundus camera.

C. Flowchart

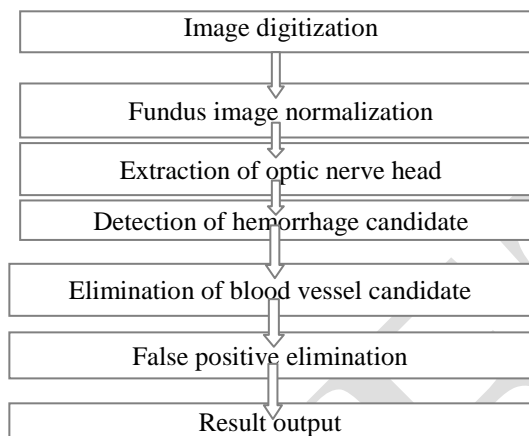


Figure 3. Flow diagram of brightness correction method [2]

D. Normalization

“Normalize” works on RGB, Grayscale, and Indexed images. Normalization is a process that changes the range of pixel intensity values. Normalization is sometimes called contrast stretching or histogram stretching. There is a typical change in the color of the fundus images, a scheme of brightness correction using hue saturation value (HSV) space. First, the brightness values of the HSV space were calculated. The brightness correction value $BC(i, j)$ is given by the following equation:

$$BC(i, j) = 1 - \{V(i, j) - 1\}^2$$

Where $V(i, j)$ is the brightness value of the HSV space.

$$V(i, j) = \text{MAX}(R(i, j), G(i, j), B(i, j))$$

Next, the red value $R(i, j)$, green value $G(i, j)$, and blue value $B(i, j)$

E. Extraction of optic nerve head

By selecting only the green component convert color image into grayscale image. Thus achieving a clearer contrast is obtained as compare to the original images, which include all the color components. After the optic nerve head is highlight with brightness greater than that used for highlighting other tissues. The shape of the detected region was approximated to a circle.

F. Detection of hemorrhage candidate

Brightness method was modification of hybrid method so for detection of hemorrhage there was template matching technique used. And for get exact shape of hemorrhage region growing segmentation technique used which was previously used in hybrid method.

G. Elimination of incorrectly detected vessels

The images of the retinal vessel include those reflected from the arterial wall. Therefore, it was difficult to detect all the vessels up to the end by using the method. By changing the threshold value such type of difficulties reduced. Hemorrhage candidates are connected to the vessel candidates. Therefore, this method cannot separate the connected candidates into hemorrhage and vessel candidates. Firstly, the threshold value is selected in such a manner that the vessels can be continuously detected. The centerlines of the vessels are extracted by using a thinning technique. Subsequently, the centerlines with large areas are extracted in such a manner that the hemorrhage candidates cannot be extracted. [2]

International Journal of Innovative Research in Science, Engineering and Technology

(An ISO 3297: 2007 Certified Organization)

Vol. 3, Issue 9, September 2014

VI. RESULTS FOR HYBRID METHOD

A. Hybrid method

Table 1. Preprocessing performance

	Tp	Tn	Fp	Fn	Sensitivity
no pre-processing					
image 1	4	2	49	0	1.0
image 2	9	2	23	0	1.0
Clahe					
image 1	4	2	49	0	1.0
image 2	11	2	23	0	1.0

Table 2 Results of foveal filter

	Tp	Tn	Fp	Fn	Sensitivity
Before					
image 1	4	36	36	0	1
image 2	10	15	15	2	0.8
After					
image 1	3	2	2	1	0.75
image 2	5	1	1	2	0.71

Table 3. Results of varying threshold value

Threshold	Tp	Tn	Fp	Fn	Sensitivity
4	9	1	1	2	0.8
7	40	3	3	4	0.7
10	10	0	0	4	0.7
15	16	2	3	4	0.6
20	2	6	6	1	0.6

VII. RESULTS FOR BRIGHTNESS CORRECTION METHOD

Table 4: Results of pre-processing process

	Tp	Tn	Fp	Fn	Sensitivity
no pre-processing					
image 1	4	2	36	0	1.0
image 2	15	0	45	0	1.0
Clahe					
image 1	4	2	36	0	1.0
image 2	9	2	15	0	1.0

Table 5: Results of foveal filter

	Tp	Tn	Fp	Fn	Sensitivity
Before					
image 1	4	49	49	0	1.0

International Journal of Innovative Research in Science, Engineering and Technology

(An ISO 3297: 2007 Certified Organization)

Vol. 3, Issue 9, September 2014

image 2	11	23	23	4	0.7
After					
image 1	4	2	2	0	1
image 2	7	3	3	2	0.77

Table 6: Results of varying threshold value

Threshold	Tp	Tn	Fp	Fn	Sensitivity
4	8	2	2	2	0.7
7	9	3	3	2	0.7
10	8	3	3	2	0.7
15	4	0	0	4	0.5

VIII. CLASSIFICATION

A. Hybrid method

Images	No of hemorrhage	Classification
image1(24)	0	Normal
image2(6)	4	Moderate NPDR
image3(40)	7	Moderate NPDR
image4(9)	35	Severe

B. Brightness correction method

IMAGES	No of hemorrhage	CLASSIFICATION
image 1(24)	0	Normal
image 2(6)	3	Moderate NPDR
image 3(40)	5	Moderate NPDR
image 4(9)	35	Severe

IX. CONCLUSION

Diabetic retinopathy is a serious complication of diabetes mellitus and a major cause of blindness worldwide. The detection of hemorrhages is one of the important factors in the early diagnosis of diabetic retinopathy (DR). Detection of hemorrhages in diabetic retinopathy is one important diagnostic criterion to determine the severity of diabetic retinopathy. Detection of hemorrhage is very important to prevent our eyes in diabetic retinopathy. A new scheme for automatically detecting hemorrhages. It was demonstrated that the algorithm detected abnormalities with higher accuracy and reliability.

REFERENCES

- [1] Jang Pyo Bae, Kwang Gi Kim, Ho Chul Kang, Chang Bu Jeong, KyuHyungPark, and, "A Study on Hemorrhage Detection Using Hybrid Method in Fundus Images" Hwang Journal of Digital Imaging, Vol 24, No 3 (June), 2011
- [2] Giri Babu Kande, T. Satya Savithri, and P. Venkata Subbaia, "Automatic Detection of Microaneurysms and Hemorrhages in Digital Fundus Images," Journal Of Digital Imaging, Vol 23, No 4 (August), 2010
- [3] Hatanaka Y, Nakagawa T, Hayashi Y, Hara T, Fujita H: "Improvement of Automated Detection Method of Hemorrhages in Fundus Images." IEEE EMBS Vancouver, Canada, 2008
- [4] Alan d, Fleming, Sam Philip, Keith A. Goat man, John A. Olson, and Peter F. Sharp. "Automated Micro aneurysm Detection Using Local Contrast Normalization and Local Vessel Detection" IEEE transactions on medical imaging, vol. 25, no. 9, September 2006

International Journal of Innovative Research in Science, Engineering and Technology

(An ISO 3297: 2007 Certified Organization)

Vol. 3, Issue 9, September 2014

[5] R. Vidyasari¹, I. Sovani², and T.L.R. Mengko³, H. Zakaria, "Vessel Enhancement Algorithm in Digital Retinal Fundus Micro aneurysms Filter for Nonproliferative Diabetic Retinopathy Classification" School of Electrical Engineering International Conference on Instrumentation, Communication, Information Technology and Biomedical Engineering, 8-9 November 2011, Bandung, Indonesia.

[6] Sunita Poddar, Bibhash Kumar Jha, Chandan Chakraborty, "Quantitative Clinical Marker Extraction from Color Fundus Images for Non-Proliferative Diabetic Retinopathy Grading" 2011 International Conference on Image Information Processing (ICIIP 2011) Indian Institute of Technology, Kharagpur, India

IJRSET