

Macular Degeneration Detection in Retinal Fundus Images using Differential Algorithm

Priya Rani¹, Jaspreet Singh Kaleka²

P.G. Student, Department of Electronics and Communication Engineering, Punjabi University, Patiala, India¹

Assistant Professor, Department of Electronics and Communication Engineering, Punjabi University, Patiala, India²

ABSTRACT: In this paper, a system is presented to detect age-related macular degeneration (AMD) from colour fundus photographs automatically. Worldwide, AMD is a major cause of blindness. This disease is highly associated with old age and often seen in people over the age of 65. Drusens are initial symptoms of AMD. The algorithm has been developed for automatic detection of age-related macular degeneration using image processing techniques. The algorithm first detect location of optic disc and then evaluates drusen area in colour fundus. The proposed system is tested on a sample set of 16 fundus images from STARE database.

KEYWORDS: Retinal fundus image, age related macular degradation, optic disc, drusen.

I. INTRODUCTION

In India, Macular degeneration is one of the most popular retinal diseases. Mostly it is observed in people over the age of 65 and is therefore called age related Macular degeneration. The layer of light sensitive tissue at the back of the eye is called the retina. The central part of the retina where the incident rays of light are focused is called macula. AMD affects the macula whose main function is to provide the sharp central vision. Age related macular degeneration is the degradation of the macular area. This degeneration effects the macula cells and respond inactive thus stop sensing. The visual cells simply stop functioning with age. In the beginning the central vision may be blurred or deformity, objects seem to be unusual shape or size. This process either may arise quickly or may grow over in a few months or may cause some trouble infrequently, but otherwise macular degeneration is not painful. Over a time a dark spot or blank patch at the centre of their vision is often noticeable in many people's which is advanced AMD. With this it makes difficulty in activities like reading, writing and recognising small objects or faces. In AMD the pigmented cells of the macula has changed. The tiny yellowish deposits appear on macula called drusens. The presence of small drusen is normal and does not cause vision loss [1]. However, the presence of large and numerous increments in drusen raise the risk of promoting advanced AMD.

Unfortunately, age-related macular degeneration cannot be completely cured and there is no treatment available for those who experience a gradual deterioration of their sight. If the vision deteriorates rapidly, or sudden distortion of objects occurs, this can be due to excessive blood vessel growth under the retina. Laser treatment may then be possible and may prevent further deterioration. If AMD is spotted at earlier stage, further degradation of macula can be precured by laser treatment. [2].

In this paper, a system is going to be proposed to automatically detect age related macular degeneration in colour fundus images. The system first determines the optic disc location. The drusen is detected by applying the threshold, chosen from the intensity characteristics and then the pixels of optic disc will be removed from the drusen detection due to similar pixels intensity property of the optic disc to obtain true detection of drusen.

International Journal of Innovative Research in Science, Engineering and Technology

(An ISO 3297: 2007 Certified Organization)

Vol. 4, Issue 8, August 2015

II. RELATED WORK

Earlier, there were many methods which had described the automatic detection of drusen spots in retinal fundus images. Sbeh introduced the use of geodesic reconstruction based on mathematical morphology to detect drusen [3]. Ziyang Liang introduced a system which first determines the location of the macula, which was further used as a landmark for a drusen grading overlay. Then, regions of drusen were detected through a maximal region-based pixel intensity approach via RGB and HSV channels [4]. Jeyakarthykeyan suggested a texture based approach for the automatic detection of drusen. The method automatically segments drusen regions in an image portions with region of interest [5]. Hijazi introduced an approach to distinguish retinal images using a histogram based representation. More clearly, a two stage Case Based Reasoning (CBR) approach was proposed, to be applied to histogram represented retina images to identify Age-related Macular Degeneration (AMD) [6]. P. Bunel proposed a fuzzy logic approach for the drusen segmentation in retinal image. A two-step approach was used in which optimal partitioning was used to divide image into three classes i.e. image background, ambiguous regions (fuzzy regions) and already detected drusen class followed by second step which includes application of fuzzy logic method to the intermediate regions [7]. Parvathi carried out a comparative study of drusen detection techniques and concluded that model based technique is more useful since it also provides the grading information. But this approach is not good for detecting small or faint drusen [8]. In this paper, an automated system is presented for detection of drusen in colored retinal fundus images. The method consists of two phases. Firstly the optic disc is determined. Secondly the drusen is detected based on pixel intensity.

III. METHODOLOGY

The proposed method for automatic detection of macular degeneration is shown in Figure 1. It consists of following steps such as pre-processing which includes green component extraction and adaptive histogram equalization, thresholding, detection and removal of optic disc to detect true drusen pixels.

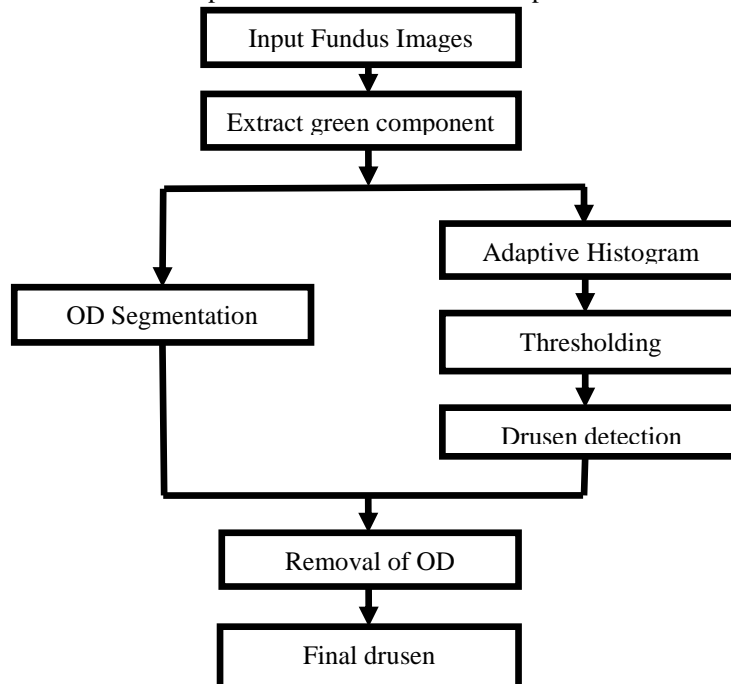


Fig.1: Flowchart of Proposed Methodology

International Journal of Innovative Research in Science, Engineering and Technology

(An ISO 3297: 2007 Certified Organization)

Vol. 4, Issue 8, August 2015

A. Pre-processing

Colour fundus images are taken from STARE database. These fundus images are classified into 3 RGB channels i.e. Red, Green and Blue. Among these three colour components, the green component is used for pre-processing as it has higher contrast between the drusen and the background. Pre-processing also consists of adaptive histogram equalization.

ADAPTIVE HISTOGRAM EQUALIZATION

Adaptive Histogram equalization is a method in digital image processing that is used to enhance the contrast of the image. This method is disparate from ordinary histogram equalization. The Ordinary histogram equalization works on whole image while adaptive histogram operates on different parts of the image and uses them to reallocate the lightness value of the image. Due to this, even local lower contrast area gains a higher contrast. This is also called as contrast-limited adaptive histogram equalization. The result of the adaptive histogram equalization is depicted in the figure 2. Figure 2 (a) shows the original image of drusen, (b) shows the green component of the original image and (c) shows the image after applying the adaptive histogram equalization.

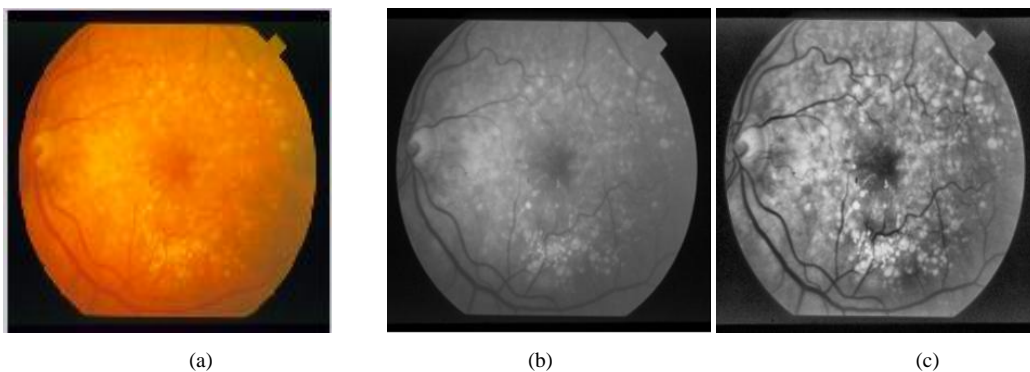


Fig. 2: (a) Original image with drusen, (b) Green Component, (c) Adaptive Histogram

B. Optic disc Removal

It is important to reveal and insulate Optic disc region because in order to detect drusen pixel intensity, the OD (optic disc) region is detected as false abnormality [9]. Therefore, the OD pixels should be removed from the calculations of accuracy of an AMD detection algorithm. The proposed method is used to pinpoint the Optic Disc in fundus images of the retina automatically. Based on the properties of the OD, OD is the brightest area as compared to others in a retinal fundus image and round in shape, so our proposed method includes steps like median filter, Gaussian filter, morphological operation and circle detection using the Hough transform to detect brightest circle in the image.

The flowchart of proposed method of detection of optic disc shown in figure 3

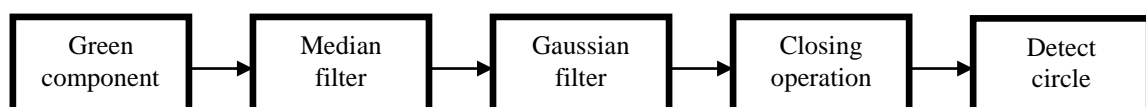

Fig. 3:Flowchart of Detection of Optic disc

International Journal of Innovative Research in Science, Engineering and Technology

(An ISO 3297: 2007 Certified Organization)

Vol. 4, Issue 8, August 2015

After performing the preprocessing, the resultant images are further fixed using a 21by21 median filter to remove the noise by preserving the edges present in the image. The result of the application of the median filtering technique is shown in the figure 4. Figure 4 (a) shows the original image of drusen, (b) shows the image after applying median filter and (c) shows the image after applying the Gaussian filter.

$$y[m, n] = \text{median} \{ x[i,j],(i,j) w \}$$

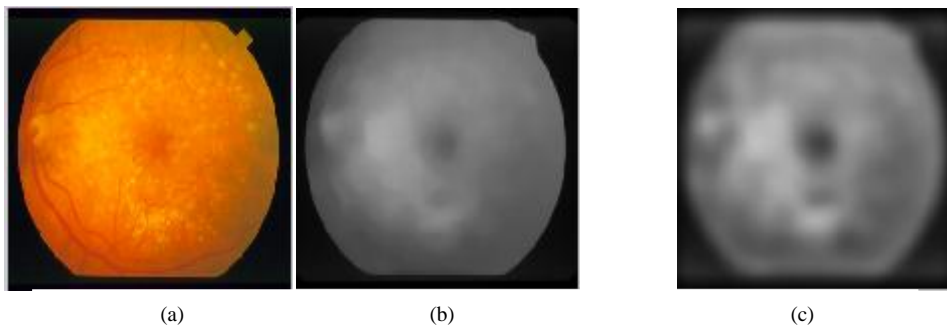


Fig. 4: (a) Original image with drusen, (b) Median filter, (c) Gaussian filter

Gaussian filters are used for blurring. A symmetric Gaussian low pass filter was applied of size 25by25 with standard deviation sigma 8. After that a morphological closing operation is done to remove all dark features that can't include the structuring element and it fills the depressions in the surface.

Then applying Hough transform to detect the rounded objects. As the Hough transform provides the center and radius of a circle that approximates the margin of the OD. Then the output image is computed by drawing circle, using centre points and the radius obtained from Hough transform and shows this on the input images. Figure 5 (a) shows the image after closing operation and (b) shows the image with optic disc detection marked as red circle.

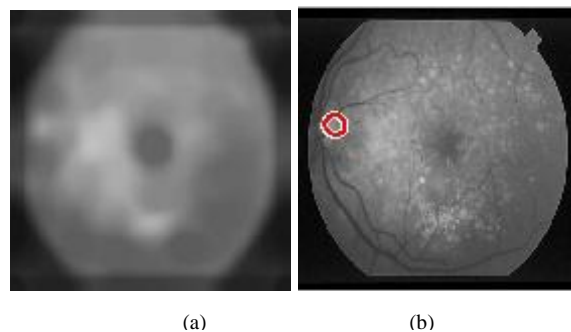


Fig. 5: (a) Closing operation, (b) Optic disc detection

C. Drusen Detection

In the images of retinal fundus, drusen appears as yellow spot across a red/orange background, so drusen information has uniqueness in intensity contrast which can be observed from the monochromatic image which helps to use the green band. In green channel, after performing adaptive histogram equalization, the drusen spots are visible in higher visibility because of its high intensity. After that, threshold is applied to extract the high intensity drusen spots. Figure 6 (a) shows the detected drusen after applying threshold and also includes optic disc pixels which is a false result. Then removal of the optic disc pixels from the detection is done and remaining pixels are true detection of

International Journal of Innovative Research in Science, Engineering and Technology

(An ISO 3297: 2007 Certified Organization)

Vol. 4, Issue 8, August 2015

drusen. Figure 6 (b) shows the image with true detection of drusen . Figure 6 (c) shows the original image with drusen detection .




Fig. 6 (a) Drusen Detection with OD pixels (b) True Drusen detection (c) Drusen Detection on Original image

IV. RESULTS AND DISCUSSIONS

The Graphical user interface of Drusen detection was created in MATLAB software. Figure 7 shows the GUI for drusen detection which includes various operations and corresponding to that operation the resultant output image is obtained.

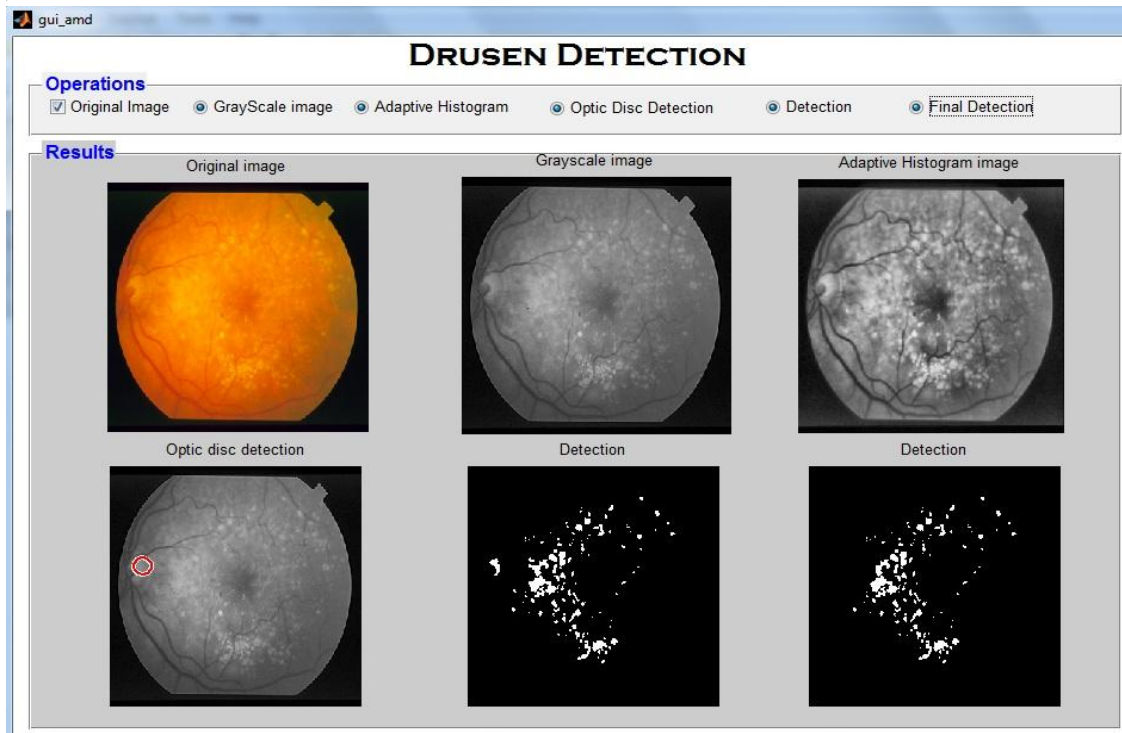


Fig.7.GUI of Drusen Detection ((1) Original Input image, (2) Gray scale image , (3) Adaptive Histogram image , (4) Optic disc detection , (5) Detection of drusen after applying threshold, (6) Final detection of drusen after removal of OD pixels)

International Journal of Innovative Research in Science, Engineering and Technology

(An ISO 3297: 2007 Certified Organization)

Vol. 4, Issue 8, August 2015

The proposed method is successfully worked on 17 retinal fundus images collected from STARE Database. We tested the images and have calculated the sensitivity and specificity of the proposed system. Sensitivity is the ability to detect correctly positive results of drusen. Numerically sensitivity is equal to the number of true positive (TP) results by the sum of true positive and false negative (FN) results.

$$\text{Sensitivity} = TP / (TP + FN)$$

Specificity is the ability to detect correctly negative results without drusen. Numerically, specificity is equal to the number of true negative results (TN) by the sum of true negative and false positive (FP) results.

$$\text{Specificity} = TN / (TN + FP)$$

Using the results, the achieved sensitivity, specificity and accuracy is 0.857, 0.667 and 0.8235 respectively

V. CONCLUSION

Age-related macular degeneration causes blindness worldwide, often seen in aged people. AMD cause central vision deteriorates resulting dark spots. The retinal disease needs to be detected in early stage to avoid further losses. However, current methods of assessment are still handed manually. In this paper, proposed system is to detect the presence of drusen in retinal image automatically, which has a strong association with AMD. This system detects both the optic disc and drusen. Then removal of optic disc pixels is done to obtain true detection of drusen in retinal fundus images by applying the digital image processing. In future, main focus will be on improving the performance of the method to pick out individual regions of drusen by applying image segmentation technique and to execute that method on a large data set. Successful implementation of the method will be used as a clinical tool for AMD screening.

REFERENCES

- [1] R. Priya and P. Aruna, "Automated diagnosis of Age-related macular degeneration from color retinal fundus images," Electronics Computer Technology (ICECT), 3rd International Conference, 2011.
- [2] R. Manjula Sri, Ch. Madhubabu, K.M.M.Rao, "Automatic Detection of Age-related Macular Degeneration from Retinal Images," International Journal of Computing Science and Communication Technologies, vol.5 no. 2, Jan. 2013.
- [3] Z. B. Sbeh and L. D. Cohen, "A New Approach of Geodesic Reconstruction for Drusen Segmentation in Eye Fundus Images," IEEE Trans. Med. Imag., Vol. 20, Dec, 2001.
- [4] Z. Liang, D. W. K. Wong, J. Liu, K.-L. Chan and T. Y. Wong, "Towards automatic detection of age-related macular degeneration in retinal fundus images," Engineering in Medicine and Biology Society (EMBC), Annual International Conference of the IEEE, 2010.
- [5] C. Jeyakarthikeyan and C. Jayakumari, "Automated Drusen Detection in Age-Related Macular Degeneration," International Journal, vol. 1, no. 7, 2013.
- [6] M. H. A. Hijazi, F. Coenen and Y. Zheng, "Retinal image classification using a histogram based approach," IEEE International Joint Conference on Neural Networks, 2010
- [7] A. Thaibaoui, A. Rajn, P. Bunel, "A Fuzzy Logic Approach to Drusen Detection in Retinal Angiographic Images, IEEE 15th International Conference on pattern recognition, pp. 748-751, 2000.
- [8] SS Parvathi, N. Devi, "Automatic Drusen Detection from Color Retinal Images", IEEE International Conference on computational Intelligence and Multimedia Applications, pp. 377-381, 2007.
- [9] G.FerdicMashakPonnaiah and Capt. Dr.S.SanthoshBaboo, "Automatic Optic Disc Detection and Removal of False Exudates for Improving Retinopathy Classification Accuracy" International Journal of Scientific and Research Publications, Vol 3, Issue 3, March 2013