

International Journal of Innovative Research in Science, Engineering and Technology

(An ISO 3297: 2007 Certified Organization)

Vol. 5, Issue 3, March 2016

Cutaneous Manifestations of Vitamin B12 Deficiency

Dr.Richa Arora¹, Dr.Avinash Dalal²

P.G. Student, Department of Dermatology, BVP Medical College, Pune, Maharashtra, India¹

Associate Professor, Department of Dermatology, BVP Medical College, Pune, Maharashtra, India²

ABSTRACT: To determine cutaneous manifestations of vitamin B12 deficiency and correlate various skin changes seen with vitamin B12 deficiency. An observational, cross-sectional, hospital based study was carried out in patients of Department of Dermatology during the period of 15 months. Total 60 study subjects (both male and females) of aged between 10 to 50 years were taken in the study. Sixty patients were tested for vitamin B12 deficiency. Among them skin hyperpigmentation was observed in 26 (43.3%) cases, Hair changes in 16 (26.7%) patients, Angular cheilitis was noticed in 14 (23.3%) patients and Vitiligo was observed in 4 (6.7%) cases. Mean serum level of B12 was 124.31 ± 49.7 pg/ml of studied population. Vitamin B12 deficiency is not uncommon in the central parts of India, contrasting the previous thoughts. Cutaneous manifestations associated with vitamin B12 deficiency were skin hyperpigmentation, hair changes, angular cheilitis, and vitiligo. We found significant correlation of mean serum vitamin B12 level with different skin changes.

KEYWORDS: Vitamin B12 deficiency, Cutaneous manifestations, Angular cheilitis, low serum level of B12, adenosylcobalamin

I. INTRODUCTION

The human body needs vitamin B12 to make red blood cells, nerves, DNA, and carry out other functions. The average adult should get 2.4 micrograms a day. Like most vitamins, B12 can't be made by the body. Instead, it must be derived from food or supplements.¹ Vitamin B12 (cobalamin) plays an important role in DNA synthesis and neurologic function. Deficiency can lead to a wide spectrum of hematologic and neuropsychiatric disorders that can often be reversed by early diagnosis and proper treatment. The National Health and Nutrition Examination Survey estimated that 3.2% of adults over age 50 years have a seriously low B12 level, and up to 20% may have a borderline deficiency.¹ The true prevalence of vitamin B12 deficiency in the general population is unknown. The incidence, however, appears to increase with age.

There are various cutaneous findings associated with cobalamin deficiency, the majority of which are more prevalent in patients with darker skin type. A retrospective and prospective study of 63 individuals with vitamin B12 deficiency related neurological syndromes in India showed that 41 % had skin and mucosal changes, with cheilitis in 31 %, hyperpigmentation in 19 %, hair changes in 9 %, angular cheilitis in 8 %, and vitiligo in 3 %.²

The pattern of hyperpigmentation is generalized with accentuation in flexural areas, palms, soles, and the oral cavity. It may also be accentuated in areas of pressure, such as the terminal phalanges, knees, and elbows. Hyperpigmentation may be the first manifestation of vitamin B12 deficiency.³ Additionally, you can see linear streaks on the nails and hair changes including poliosis.⁴

Vitamin B12 deficiency and depletion are common in wealthier countries, particularly among the elderly, and are most prevalent in poorer populations around the world.⁵ Vitamin B12 deficiency shows increased melanin in the basal layer of the epidermis. One electron microscopic study showed many melanosomes in melanocytes and surrounding keratinocytes. The dominant mechanism of hyperpigmentation due to vitamin B12 deficiency is an increase in melanin synthesis.⁶ Vascular endothelial growth factor, which may have promoted the angiogenesis in this patient and could represent a mechanism for the hyperpigmentation from cobalamin deficiency.⁷

International Journal of Innovative Research in Science, Engineering and Technology

(An ISO 3297: 2007 Certified Organization)

Vol. 5, Issue 3, March 2016

II. RELATED WORK

There are limited studies dedicated to the assessment of the dermatological manifestation of the vitamin B12 deficiency. The main objective of the present study to determine cutaneous manifestations of vitamin B12 deficiency, their effects seen on the various skin changes and to correlate the skin changes with vitamin B12 levels. This was an observational cross sectional study done in the dermatology OPD of a tertiary care hospital.

A total of 60 patients were clinically diagnosed and confirmed by Vitamin B12 levels.

A detailed history was taken including the onset, duration & progress of the condition, past history & family history of similar complaints. Patients were investigated for Haemogram and Vit B12 levels.

A detailed clinical examination was done & photographic records were maintained

III. SCOPE OF RESEARCH

Vitamin B12, also known as cobalamin, is a water soluble vitamin that is very important in the hematological and nervous systems. It exists in many forms in the body, two of which are biologically active coenzymes: methylcobalamin and adenosylcobalamin. Methylcobalamin is a coenzyme with methionine synthase, a key enzyme in the folic acid dependent synthesis of pyrimidines and purines.

Cobalamin has a complex uptake and metabolism that requires several coenzymes. When cobalamin is ingested from food sources, it is first released from the proteins in food by pepsin in the stomach. It then binds to haptocorrin, which is found in saliva and protects cobalamin from the acidic environment of the stomach. Haptocorrin is then degraded in the duodenum by digestive proteases and the free cobalamin binds to intrinsic factor. Intrinsic factor is needed for cobalamin to be absorbed by receptors on the enterocytes in the terminal ileum and to protect it from catabolism by intestinal bacteria. Cobalamin is then transported into the portal circulation and taken up by the liver. The majority of cobalamin in circulation is bound to haptocorrin, with a smaller percentage bound to transcobalamin II, and a negligible amount of circulating free cobalamin.⁸ It is taken up into tissues, mainly the liver, via transcobalamin receptors, which are located on endothelial cells and not hepatocytes themselves. The liver stores enough cobalamin to last several years before symptoms of deficiency present.⁹ Due to the complexity of the metabolism and absorption of cobalamin, there are many opportunities for defects to occur, which can result in deficiency or imbalance.

Epidemiology of Vitamin B12 Deficiency:-

Worldwide Studies of Vitamin B12 Deficiency: Vitamin B12 deficiency was first described by Cook¹⁰ in 1944 and later by Baker et al¹¹ in 1963. A deficiency can be caused by a congenital lack of transcobalamin II, a lack of intrinsic factor, achlorhydria, ileal disease, malnutrition, and malabsorption syndrome.¹² Vitamin B12 deficiency usually occurs 3 to 6 years after the onset of gastrointestinal abnormalities because of the large body stores found in adults.¹² There is multisystem involvement in this deficiency, with the skin, central nervous system, and bone marrow being affected.¹²

In the United Kingdom and United States the prevalence of vitamin B12 deficiency is around 6% in people aged less than 60 years, and closer to 20% in those aged more than 60 years. Across Latin America approximately 40% of children and adults have clinical or subclinical deficiency. The prevalence of deficiency is much higher in African and Asian countries—for example, 70% in Kenyan schoolchildren, 80% in Indian preschool children, and 70% in Indian adults.¹³ Pawlak et al¹⁴ studied the prevalence of cobalamin deficiency among vegetarians assessed by serum vitamin B12 and they reported that relatively high deficiency prevalence among vegetarians. Vegetarians who do not ingest vitamin B12 supplements were found to be at especially high risk.

Indian Studies of Vitamin B12 Deficiency:

The incidence of B12 and folate deficiency in India is unknown but recent evidence suggests that it is commoner than we thought. Some years ago Dasture et al¹⁵ reported 5 cases with neurological manifestation of B12 deficiency, over several years in Bombay. Among 450 cases, B12 deficiency (level below 200pg/ml) was detected in 0.88%, folic acid deficiency (level below 3 g/ml) in 1.1% and deficiency of both in 2.4% of patients. 3.8% of cases had levels near the lower limit of normal.

Vineeta Shobhaa et al¹⁶ studied the vitamin B12 deficiency & levels of metabolites in an apparently normal urban south Indian elderly population and they concluded that indicative of higher vitamin B12 (2.4 µg/day) intakes in urban south Indian population. Thirty five per cent of the study population consumed multivitamin supplements and

International Journal of Innovative Research in Science, Engineering and Technology

(An ISO 3297: 2007 Certified Organization)

Vol. 5, Issue 3, March 2016

therefore, low plasma vitamin B12 levels were seen only in 16 per cent of the study subjects. However, MMA was elevated in 55 per cent and HCY in 13 per cent of the subjects.

Sen K et al¹⁷ studied of clinical profile of vitamin B₁₂ deficiency with special reference to dermatologic manifestations in a Tertiary Care Hospital in sub-Himalayan Bengal and they concluded that the Vitamin B₁₂ deficiency is not uncommon in the eastern parts of India, contrasting the previous thoughts that it was uncommon in this area, though larger studies are required to know it better. Their study included only those requiring blood transfusions, thus a much higher prevalence is expected in this area. Patients with vitamin B₁₂ deficiencies do present with severe anemia requiring blood transfusions and often have skin hyperpigmentation.

Monica Gupta and Ram Singh¹⁸ studied the Knuckle Hyperpigmentation Associated with Vitamin B12 Deficiency and they reported that the Pancytopenia due to vitamin B12 deficiency is very common in the predominantly vegetarian population. They emphasize the clinical sign of knuckle hyper pigmentation as an important clue towards the etiology of pancytopenia.

IV. METHODOLOGY AND DISCUSSION

An observational, cross-sectional, hospital based study was carried out in patients during the period of 15 months . Total 60 study subjects (both male and females) of aged between 10 to 50 years were taken.

The sample size was estimated on the basis of a single proportion design. The study population was drawn from the patient who fulfill the criteria for Vitamin B12 Deficiency comprised of those attended the outpatient department.

Patients with skin manifestation of vitamin B12 deficiency like knuckle pigmentation, vitiligo, hair colour changes and angular cheilitis were included.

Pre-designed proforma for data collection was done. Diagnosis is based on vitamin B12 levels and haemogram. The cutoff points used for vitamin B12 was 200 pg/mL, normal range 200 to 900 pg/mL

After informed consent was obtained, all details of each patients such as socio-demographic characteristics such as age, gender, nationality, height, weight, and consanguineous marriage, physical activity and lifestyle habits like smoking and alcohol and biochemistry laboratory investigations such as haemogram, vitamin B12 was recorded in the patient proforma.

Fasting blood samples were obtained from all participants in tubes without anticoagulant, for measurement of vitamin B12. Serum and plasma samples were processed within 3 hours of collection and stored below -80°C until analyses

Serum levels of vitamin B12 were determined using chemiluminescence immunoassays (Elecsys/Roche Diagnostics, Mannheim, Germany).

Data was analyzed using SPSS version 20 (SPSS Inc., Chicago, IL). Student's *t*-test was used to ascertain the significance of differences between mean values of two continuous variables and confirmed by nonparametric Mann-Whitney test. Multiple linear regression analysis with stepwise criteria was performed for folate, vitamin B12, with age, body mass index, as the independent variables. The level $P < 0.05$ was considered as the cutoff value or significance.

The over all mean of age of patients was 36.9 ± 20 years and mostly (83.3%) were females in present study. Our study population, however, was younger than populations in some previous studies and we found an unusually high rate of deficiency in people younger than older age.

Interestingly, vitamin B12 deficiency was found to be more common than was expected. Raised MCV (>100 fl) was found in 69% of patients. Skin hyperpigmentation was observed in 26 (43.3%) cases, Hair changes in 16 (26.7%) patients, angular cheilitis was noticed in 14 (23.3%) patients and vitiligo was observed in 4 (6.7%) cases in our study. The mechanism of hyperpigmentation is due to increased melanin synthesis rather than a defect in melanin.¹⁹ The main source of vitamin B12 (cobalamin) in humans is the consumption of meat, poultry and dairy products. The recommended dietary allowance for a standard adult is 2.4 µg/day. Generally vitamin B12 deficiency is seen in nutritionally poor diet in low socio-economic groups, vegetarians, pernicious anemia, chronic drug intake (e.g. phenytoin and acid-suppressing medication), increased requirements during growth and pregnancy and in malabsorption syndromes.²⁰ It is also observed in patients with eating disorders like anorexia nervosa, bulimia nervosa, pica or other psychiatric disorders. Cutaneous manifestations associated with vitamin B12 deficiency were found significant in various skin changes. ($p < 0.001$).

International Journal of Innovative Research in Science, Engineering and Technology

(An ISO 3297: 2007 Certified Organization)

Vol. 5, Issue 3, March 2016

V. EXPERIMENTAL RESULTS

Demographic and clinical profile of B12 deficient patients

Table no 1 shows number of patients according to their age categories.

Age categories	No. of patients
10 – 20	5
20 – 30	10
30 – 40	32
40 – 50	13
Total	60
Mean±SD (Range)	36.9±20.9 (10 – 50)

SD= Standard deviation

Table no 2 shows gender of studied patients.

Gender	Frequency (%)
Male	10 (16.7%)
Female	50 (83.3%)
Total	60 (100%)

Table no 3 shows food habits of patients drafted for study.

Diet	Frequency (%)
Vegetarians	13 (21.7%)
Non-Vegetarians	47 (78.3%)
Total	60 (100%)

Table no 4 shows skin changes of patients under evaluation.

Skin changes	Frequency (%)
Yes	47 (78.3%)
No	13 (21.7%)
Total	60 (100%)

International Journal of Innovative Research in Science, Engineering and Technology

(An ISO 3297: 2007 Certified Organization)

Vol. 5, Issue 3, March 2016

Chart No 1 showing skin and mucosal changes in the studied patients.

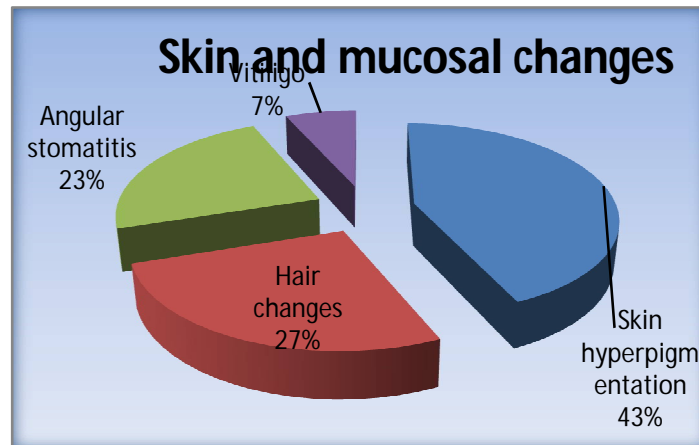
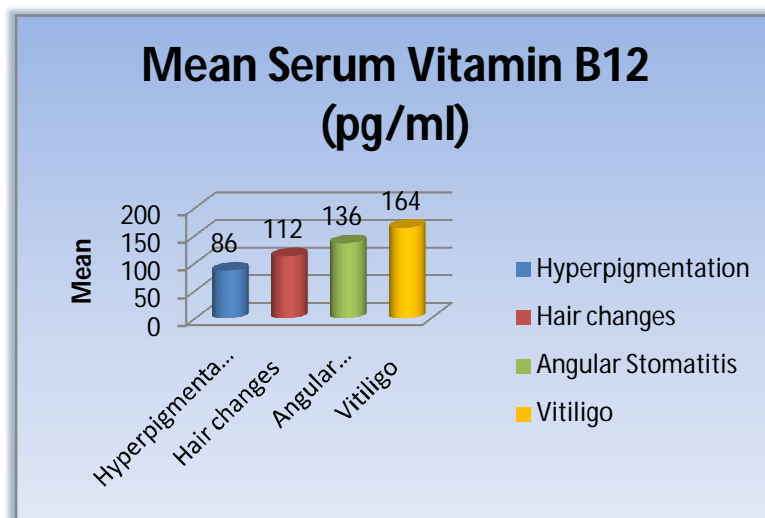


Table 5. shows Mean Serum Vitamin B12 (pg/ml) of studied patients.

Skin and Mucosal Changes	Mean Serum Vitamin B12 (pg/ml)	P value
Hyperpigmentation	86.00±8.5	<0.001
Hair changes	112.00±12.6	
Angular cheilitis	136.00±11.4	
Vitiligo	164.00±23.2	
Total	124.5±15.6	

Chart no 2. Bar graph shows Mean Serum Vitamin B12 (pg/ml) of studied patients.



International Journal of Innovative Research in Science, Engineering and Technology

(An ISO 3297: 2007 Certified Organization)

Vol. 5, Issue 3, March 2016

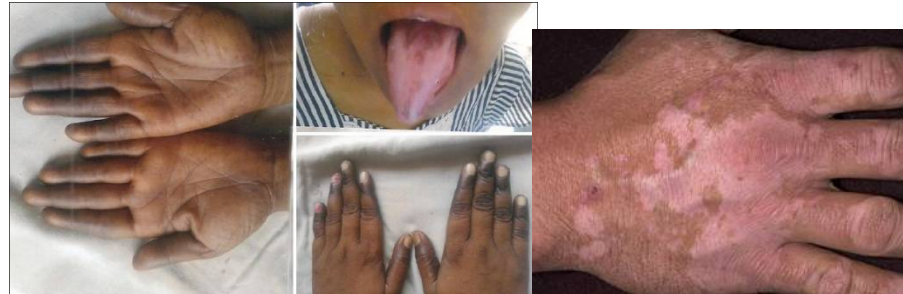

Figure 1&2Figure 3

Figure 1&2 shows hyperpigmentation of palm, creases and tongue due to deficiency of vitamin B12
Figure 3 shows vitiligo in a patient of vitamin B12 deficiency

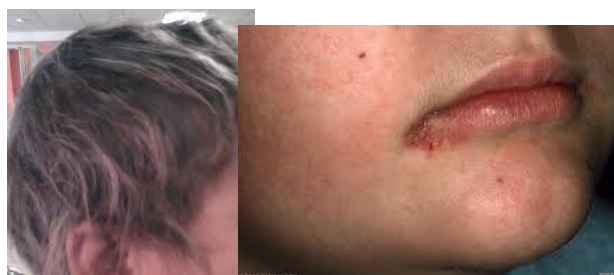

Figure 4

Figure 5

Figure 4 showing greying of hair as a result of vitamin B12 deficiency
Figure 5 shows angular cheilitis in a patient of vitamin B12 deficiency

VI. CONCLUSIONS

1. The overall mean age of patients was 36.9 ± 20 years.
2. Females are more dominant than males. Due to the eating habit.
3. Mostly patients were vegetarian.
4. Neurological involvement was rather uncommon, found in only 23.3% even at very low serum vitamin B12 levels.
5. Skin hyperpigmentation was observed in 26 (43.3%) cases, Hair changes in 16 (26.7%) patients, Angular cheilitis was noticed in 14 (23.3%) patients and Vitiligo was observed in 4 (6.7%) cases.

ACKNOWLEDGEMENT

The completion of this work could not have been possible without the participation and guidance of so many people whose names may not all be enumerated. Their contributions are sincerely appreciated and gratefully acknowledged. I would like to express my deep appreciation and indebtedness to the following:

Dr. VR Sardesai (HOD, dept. of dermatology)

Dr. Avinash Dalal (Ass. Prof. dept. of dermatology)

To all relatives, friends and others who supported either morally, financially and physically, thank you.

International Journal of Innovative Research in Science, Engineering and Technology


(An ISO 3297: 2007 Certified Organization)

Vol. 5, Issue 3, March 2016

REFERENCES

1. Patrick J. Skerrett, Vitamin B12 deficiency can be sneaky, harmful. Harvard Health Publications, January 10, 2013;
2. Aaron S, Kumar S, Vijayan J, Jacob J, Alexander M, Gnanamuthu C. Clinical and laboratory features and response to treatment in patients presenting with vitamin B12 deficiency-related neurological syndromes. *Neurol India*, 2005; 53(1):55-8
3. Srivastava N, Chand S, Bansal M, Srivastava K, Singh S. Reversible hyperpigmentation as the first manifestation of dietary vitamin B12 deficiency. *Indian J Dermatol Venereol Leprol*, 2006; 72:389-90.
4. Niiyama S, Mukai H. Reversible cutaneous hyperpigmentation and nails with white hair due to vitamin B12 deficiency. *Eur J Dermatol*, 2007; 17(6):551-2.
5. Lindsay H Allen. How common is vitamin B-12 deficiency. *Am J Clin Nutr*, 2009; 89:693-96.
6. Mori K, Ando I, Kukita A. Generalized hyperpigmentation of the skin due to vitamin B12 deficiency. *J Dermatol*, 2001; 28(5):282-5.
7. Aroni K, Anagnostopoulou K, Tsagroni E, Ioannidis E. Skin hyperpigmentation and increased angiogenesis secondary to vitamin B12 deficiency in a young vegetarian woman. *Acta Derm Venereol*, 2008; 88(2):191-2.
8. Ermens AA, Vlasveld LT, Lindemans J. Significance of elevated cobalamin (vitamin B12) levels in blood. *Clin Biochem*. 2003;36(8):585-90.
9. Kozyraki R, Cases O. Vitamin B12 absorption: mammalian physiology and acquired and inherited disorders. *Biochimie*. 2013; 95(5):1002-7.
10. Cook BA. A vitamin B12 deficiency syndrome allied to sprue. *Indian Med Gaz*. 1944;79:429-437.
11. Baker SJ, Johnson S, Ignatius H, et al. Hyperpigmentation of the skin: a sign of vitamin B12 deficiency. *Br Med J*. 1963;1:1713-1715.
12. Fathman EM, Geisel EB, Salmo A. Nutritional diseases. In: Odom RB, James WD, Berger TG. *Andrews' Diseases of the Skin: Clinical Dermatology*. 9th ed. Philadelphia, Pa: WB Saunders Co; 2000:606-615.
13. Allen L. How common is vitamin B-12 deficiency? *Am J Clin Nutr*, 2009; 89(suppl):S693-6.
14. Pawlak R, Lester SE, Babatunde T. The prevalence of cobalamin deficiency among vegetarians assessed by serum vitamin B12: a review of literature. *Eur J Clin Nutr*. 2014 May;68(5):541-8. doi: 10.1038/ejcn.2014.46.
15. Dastur DK, Quaddros EV, Wadia NH et al : Effect of vegetarianism and smoking on vitamin B12, thiocyanate, and folate levels in the blood of normal subjects. *BMJ* 1972; 3 : 260-264.
16. Vineeta Shobhaa, Subhash D. Tareya, Ramya G. Singhe, Priya Shetty, Uma S. Unnid, Krishnamachari Srinivasane & Anura V. Kurpadb. Vitamin B12 deficiency & levels of metabolites in an apparently normal urban south Indian elderly population. *Indian J Med Res* 134, October 2011, pp 432-439.
17. Sen K, Sinhamahapatra P, Lalhmachhuana J, Ray S. A study of clinical profile of vitamin B 12 deficiency with special reference to dermatologic manifestations in a Tertiary Care Hospital in sub-Himalayan Bengal. *Indian J Dermatol*, 2015;60:419.
18. Monica Gupta and Ram Singh. Clinical Sign Revisited: Knuckle Hyperpigmentation Associated with Vitamin B12 Deficiency. *Austin J Clin Case Rep*. 2014;1(2): 1007.
19. Mori K, Ando I, Kukita A. Generalized hyperpigmentation of the skin due to vitamin B12 deficiency. *J Dermatol*. 2001 May;28(5):282-5.
20. Khanduri U, Sharma A. Megaloblastic anaemia: prevalence and causative factors. *Natl Med J India*. 2007 Jul-Aug;20(4):172-5.

BIOGRAPHY



Dr. Richa Arora I am pursuing postgraduate degree in dermatology from BVP medical college, Pune . I have done my MBBS from C.C.U Meerut. I have keen interest in the field of dermatosurgery & cosmetology. I have presented this topic in national conference also.