

Survey on Automatic Detection of Glaucoma based on Eye Images

Rakhi Ramachandran Nair^{#1}, Chippy Jacob^{#2}, Tessy Vincent^{#3}, Remyamol.R^{#4}

PG Scholar, Dept. of Computer Science & Engineering, College of Engineering, Kidangoor, Kottayam, India^{#1,2,3}

Assistant Professor, Dept. of Information Technology, College of Engineering, Kidangoor, Kottayam, India^{#4}

ABSTRACT: Glaucoma is a chronic eye disease that may lead to loss of vision, if not detected earlier. It occurs mainly due to the breakdown of optic nerve at the back of the eye and increased Intraocular Pressure (IOP) within the eyes. Glaucoma damages the optic nerve which carries information from the eye to the brain. It is one of the leading causes of blindness, and studies found that around 80 million people will be affected with glaucoma by 2020. This paper deals with the effectiveness of some automatic methods to detect glaucoma. Manual analysis is much time consuming and its accuracy depends on the clinicians. So various automatic analysis schemes were introduced later. Automatic analysis is much more effective than manual analysis.

KEYWORDS: Fundus, Glaucoma, correntropy, support vector machine.

I. INTRODUCTION

Glaucoma is an irretrievable eye disease that affects the structure of nerve fibers and optic disc parameters such as diameter, volume, and area. It is the leading cause of irreversible blindness worldwide. It occurs mainly due to the increased pressure in optic nerves. A person who suffers glaucoma will have IOP more than 21 mmHg. Between the cornea and the crystalline lens there is a watery fluid named aqueous humor. It maintains the pressure needed to inflate the eye. The intraocular pressure is simply a product of the rate of aqueous production and the aqueous drainage. This balance keeps the IOP in limit. IOP increases if the balance is not maintained and damage the optic nerve head which leads to vision loss. So, the early detection and treatment will control the progression of the disease. The difference between normal eye and eye affected with glaucoma is shown in figure 1.

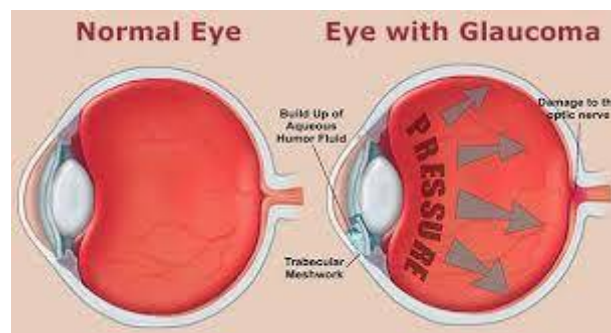


Figure 1: Normal and Glaucomatic eye

Different types of glaucoma are Open Angle/ Chronic Glaucoma, Acute Angle Closure Glaucoma, Normal Tension Glaucoma, Ocular Hypertension and Congenital Glaucoma.

Different views of same image is represented in figure 2. Main reasons for glaucoma are old age, diabetes, eye injuries, myopia, Corticosteroids, migraine, etc... There exist many methods to detect glaucoma like Heidelberg Retinal Tomography (HRT), Scanning Laser Polarimetry (SLP) and Optical Coherence Tomography (OCT). All these methods assess optic nerve. Optical Coherence Tomography (OCT) is a non-invasive imaging test that use light waves to take the cross-section pictures of your retina. With OCT the distinctive layers of retina can be seen. It helps to map and measure their thickness. This measure helps to diagnose glaucoma. Scanning Laser Polarimetry (SLP) use polarized light to measure the thickness of retinal nerve fiber layer as part of glaucoma workup. Heidelberg Retinal Tomography (HRT) is a procedure used for the diagnosis and management of glaucoma by precisely observing and documenting the optic nerve head. The Heidelberg Retinal Tomography uses a special laser (that will not affect the eye) to capture 3 dimensional photographs of the optic nerve and surrounding retina. This laser is mainly focused on the surface of the optic nerve and captures the image. But these methods are very expensive and need expert clinicians. Because of that automated diagnosis became important.



Figure 2: Schematic view of an image at different stages of vision

II. LITERATURE SURVEY

A. ANGLE OPEN DISTANCE 500 CALCULATION BY USING GUI

Glaucoma can be detected using an algorithm that automatically performs angle calculation by analyzing the eye ultrasound images. The algorithm reduce the processing time taken by the manual compute based algorithm without compromising on the speed, accuracy, sensitivity, cost and compatibility of the product with relevance of image processing concepts. To avoid the problems in image like noise, poor resolution, the following three step method is used.

i) Step-1: Ultrasound image processing

It includes the steps like, enhancement, thresholding median filtering, erosion and hole filling to curate fine image.

ii) Step--2: Segmentation of the processed image

Classification of various region of ultra sound image, eliminating the unwanted image, cropping the anterior chamber region and the location of reference axis these are the effective procedures for segmentation.

iii) Step--3: Calculation of AOD 500

It involves steps like masking determination of apex point (X apex, Y apex) location, tracing anterior chamber, AOD 500 calculations. This algorithm is able to correctly diagnose glaucoma in 97% of the cases.

B. CUP TO DISK RATIO

Various segmentation and classification techniques are used to detect the glaucoma from the retinal images based on the Cup to Disc Ratio (CDR) evaluation of pre-processed image. In paper [2] it presents an image processing technique for segmentation of optic disc and cup as well as diagnosis of glaucoma using the features obtained from the image based on the study of adaptive thresholding technique and SVM classification technique. It includes mainly 3 steps. They are Region of Interest (ROI) Extraction, Feature extraction stage and classification stage. The K means clustering technique is recursively applied to extract the optic disc and optic cup region and an elliptical fitting technique is applied to find the CDR values. The blood vessels in the optic disc region are detected by using local entropy thresholding approach. The ratio of area of blood vessels in the inferior-superior side to area of blood vessels in the

nasal-temporal side (ISNT) is combined with the CDR for the classification of fundus image as normal or glaucoma by using Support Vector Machine. It gives accuracy improvement and sensitivity of detection of glaucoma from retinal fundus image.

C. WAVELET BASED ENERGY FEATURES

In wavelet transform (WT), the image is represented in terms of the frequency of content of local regions over a range of scales. Data is initially subjected to standard histogram equalization. Then the discrete wavelet transform features are extracted and pre-processed. Then the features are normalized using z-score normalization technique. These features are then ranked using chi squared (χ^2), gain ratio, information gain feature evaluation techniques and relief feature ranking schemes. Then the features are selected using four consistency subset evaluation strategies: best first, random search, genetic search and greedy search.

D. PRINCIPAL COMPONENT ANALYSIS, FAST FOURIER TRANSFORM & SPLINE

In paper [4] it uses a 3 step procedure for automatic detection of glaucoma. The steps are Pre-processing, Feature extraction and Classification. Pre-processing involves illumination correction, vessel removal and optic nerve head normalization. The high-dimensional pre-processed images P are statistically compressed by PCA (Principal Component Analysis) to gain compact and meaningful features 'f'. To capture complementary image information three different generic image representations is used with different spatial and frequency resolution for feature extraction. They are Pixel intensity values, B-spline coefficients and FFT coefficients. SVM classifier is used here for classification. Here a 2 stage classification scheme combines the features to find out the glaucoma risk index (GRI). First stage involves the determination of probability for normalized PCA compressed features. Second stage includes the concatenation of the probabilities to one low dimensional feature space. The GRI obtained provide an accuracy of 80% in a two class problem.

E. TEXTURE AND HIGHER ORDER SPECTRA FEATURES

Two types of features are extracted after pre-processing: 1) HOS parameters and 2) texture descriptors. HOS represents both amplitude and phase information of a signal. HOS can be used for both deterministic signals and random processes. This method is clinically significant because these features had a low p -value, which means that there is more chance that these features have very different values for the normal and abnormal classes and better discriminate the two classes [5]. Random-forest classifier, combined with z-score normalization and feature-selection methods are used for classification purpose.

F. NEURAL NETWORK AND ADAPTIVE NEURON FUZZY INFERENCE SYSTEM

A classifier based on Neural Network and Adaptive Fuzzy Inference system (ANFIS) [6] is used. It utilizes both delta rule and backpropagation algorithm. ANFIS combines the capabilities of fuzzy inference algorithms and neural networks. An adaptive neural network is a structure consists of five layers and a number of nodes connected via links. First layer perform fuzzification, second layer executes the fuzzy AND of the antecedent part of the fuzzy rules, the third layer normalizes the fuzzy membership functions, the fourth layer executes the consequent part of the fuzzy rules and finally the last layer computes the output of the fuzzy system by summing up the outputs of the fourth layer. ANFIS is a multilayer feed forward network which uses ANN learning algorithms and fuzzy reasoning to characterize an input space to an output.

G. GABOR TRANSFORM

Image features can be extracted by applying Gabor transform on fundus images. Gabor transform is a version of short time Fourier transforms. It is used to determine the sinusoidal frequency and phase content of local sections of a signal as it changes over time. Various features namely mean, variance, skewness, kurtosis, energy, and Shannon, Renyi, and Kapoor entropies are extracted from the Gabor transform coefficients. These extracted features are subjected to principal component analysis (PCA) to reduce the dimensionality of the features. Then the features are ranked using various ranking methods like Bhattachaiyya space algorithm, t-test, Wilcoxon test, etc.. But t-test ranking method

yielded the highest performance with an average accuracy of 93.10%, sensitivity of 89.75% and specificity of 96.20% using 23 features with Support Vector Machine (SVM) classifier.

H. 2D EWT AND CORRENTROPY

R,G,B components and gray scale values are extracted first[7]. Then R,G,B values are subjected to 2D empirical wavelet transform to form sub-band images. EWT is an adaptive method of signal decomposition. Band pass filters defined on each contiguous segment defines empirical wavelets. Then the correntropy is extracted from decomposed components. Correntropy is a non-linear kernelized similarity measure. Then the features showing distinction are selected using Student's t-test algorithm. Then the features are standardized with zero mean and unit standard deviation. The process is known as z-score normalization. The ranked features are classified using the Least Squares Support Vector Machine (LS-SVM) classifier with kernels such as Radial Basis Function (RBF), Morlet wavelet and Mexican-hat wavelet.

Advantages of the this method are: Obtained a sensitivity of 100%, Reported high performance using three-fold and ten-fold cross validation, Used less number of features to obtain highest classification accuracy, Performance of the system does not depend on the resolution of the image. Comparison of the above discussed methods is tabulated in table 1.

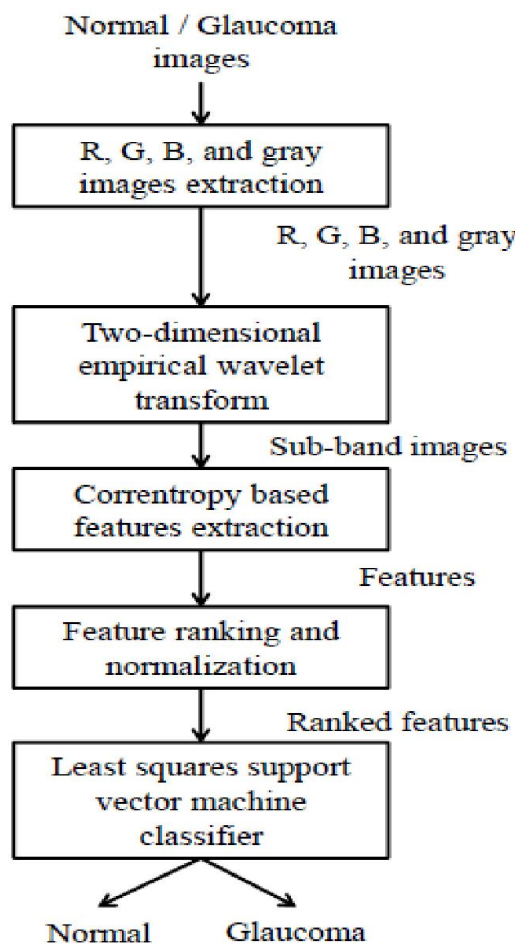


Figure 3: Block diagram of system using 2D EWT technique

International Journal of Innovative Research in Science, Engineering and Technology

An ISO 3297: 2007 Certified Organization

Volume 5, Special Issue 14, December 2016

3rd National Conference on Recent Trends in Computer Science and Engineering and Sustainability in Civil Engineering (TECHSYNOD'16)

19th, 20th and 21st December 2016

Organized by

Department of CSE, MCA &CE, Mohandas College of Engineering and Technology, Thiruvananthapuram, Kerala, India

Method Used	Accuracy	Sensitivity	Specificity
AOD 500	97	NR	NR
PCA,FFT	80	NR	NR
Gabor	93.1	89.75	96.2
HOS	95	93.33	96.67
2D EWT	98	100	96.67

*NR=Not Reported

Table 1: Comparison of various glaucoma detection techniques

III. CONCLUSION

This paper presents a literature survey of various automated glaucoma detection techniques. There are different methods through which we can detect glaucoma without the help of an efficient clinician. Compared to all these methods the one that use 2D Empirical Wavelet Transform and correntropy feature is found to be more effective. It uses Least Square-Support Vector Machine as classifier. It provides 98% accuracy, 100% sensitivity and 96.67% specificity. We can further enhance the accuracy by using Grey Level Co-occurrence Matrix features.

REFERENCES

[1] Neelapala Anil Kumar and P.A.Nageswara Rao, Prof P.Mallikarjuna Rao, Smt. M. Satya Anuradha: "Automatic detection of glaucoma in eye by angle opens distance 500 calculation by using GUI", International Journal of Science and Advanced Technology (ISSN 2221-8386) Volume 1 No 6 August 2011.

[2] K.Narasimhan, Dr.K.Vijayarekha: "An efficient automated system for glaucoma detection using fundus image", Journal of Theoretical and Applied Information Technology, 15th November 2011. Vol. 33 No.1.

[3] Sumeet Dua, Senior Member, IEEE, U. Rajendra Acharya, Pradeep Chowriappa, Member, IEEE, and S. Vinitha Sree, 'Wavelet-Based Energy Features for Glaucomatous Image Classification", IEEE Transactions on Information Technology in Biomedicine, Vol. 16, No. 1, January 2012.

[4] R. Bock, J. Meier, L. G. Ny'ul, J. Hornegger, and G. Michelson, "Glaucoma risk index: Automated glaucoma detection from color fundus images," Medical Image Analysis, vol. 14, no. 3, pp. 471-481, 2010.

[5] U. Rajendra Acharya, Sumeet Dua, Xian Du, Vinitha Sree S, and Chua Kuang Chua, "Automated Diagnosis of Glaucoma Using Texture and Higher Order Spectra Features", " IEEE Transactions on Information Technology in Biomedicine Vol. 15, No: 3, May 2011.

[6] Rohan Appasaheb Borgalli, Hari Pratap Gautam, Winner George Parayil, "Automated Glaucoma Detection Techniques Using Fundus Image", International Journal of Technology Enhancements and Emerging Engineering Research, Vol 3, Issue 12.

[7] Shishir Maheshwari, Ram Bilas Pachori, and U. Rajendra Acharya, "Automated Diagnosis of Glaucoma Using Empirical Wavelet Transform and Correntropy Features Extracted from Fundus Images", IEEE Journal of Biomedical and Health Informatics,2016.