

# Case Study: Morphological and Biochemical Blood Analysis of a Cow with Osteosarcoma

Ramūnas Antanaitis<sup>1</sup>, Mindaugas Televičius<sup>2</sup>, Zoja Miknienė<sup>3</sup>, Indrė Stasiulevičiūtė<sup>4</sup>, Giedrė Vokietytė<sup>5</sup>

Associate Professor, Large Animal Clinic of the Lithuanian University of Health Sciences, Kaunas, Lithuania<sup>1</sup>

Lecture Large Animal Clinic of the Lithuanian University of Health Sciences, Kaunas, Lithuania<sup>2</sup>

Lecture Large Animal Clinic of the Lithuanian University of Health Sciences, Kaunas, Lithuania<sup>3</sup>

Lecture Large Animal Clinic of the Lithuanian University of Health Sciences, Kaunas, Lithuania<sup>4</sup>

Lecture Large Animal Clinic of the Lithuanian University of Health Sciences, Kaunas, Lithuania<sup>5</sup>

**ABSTRACT:** This note describes the clinical, radiographic and laboratory findings in a five-year-old Holstein cow with nasal osteosarcoma. Diagnosis was confirmed by histological evaluation of a biopsy sample. A clinically healthy cow was selected for control by the principle of analogy. Blood samples for haematology and biochemical analysis were taken every week for three weeks in a row. Blood biochemical analysis indicated low calcium, iron and albumin concentrations, while the phosphorus concentration was significantly exceeded. The haematology results indicated erythropenia, lymphocytopenia, and a low white blood cell haemoglobin count. Biochemistry results indicated a low albumin, calcium and liver enzyme count.

**KEYWORDS:** Cow, osteosarcoma, facial swelling, haematology.

## I. INTRODUCTION

Osteosarcoma (OS) is a primary and aggressive bone sarcoma affecting the skeleton of two principal species, human beings and canines [2]. Osteosarcoma is a malignant tumour derived from primitive mesenchyme stem cells with the capacity to produce an osteoid matrix [2, 10]. Biologically, OS originates within the intramedullary cavity of metaphysical bone. The growth and progression of appendicular OS result in the effacement and erosion of the immediate bone microenvironment, including the marrow cavity and circumferential cortical and trabecular bone. In addition to localized skeletal perturbations, OS metastasizes to distant visceral organs, most commonly the pulmonary parenchyma via haematogenous dissemination [1,3,9]. Facial swelling in farm animals can be caused by various diseases and trauma and often involves soft tissues or bone of the oropharynx [7]. Osteosarcoma is the most common bone tumour in dogs, cats and humans, and is considered to be one of the most malignant and aggressive tumours as it is associated with a high frequency of pulmonary metastasis [10].

The aim of this study was to describe the clinical, radiographic and laboratory findings in a five-year-old Holstein cow with nasal osteosarcoma.

## II. CASE HISTORY AND CLINICAL FINDINGS

Case history and clinical findings. A five-year-old cow was delivered to the Large Animal Clinic of the Veterinary Academy of the Lithuanian University of Health Sciences. The cow was referred because of a firm, non-painful facial swelling, approximately 14 x 10 cm in diameter, which was situated on the nasal-frontal part of the skull (Figure 1).

## International Journal of Innovative Research in Science, Engineering and Technology

(An ISO 3297: 2007 Certified Organization)

Website: [www.ijirset.com](http://www.ijirset.com)

Vol. 6, Issue 2, February 2017




Fig. 1. Osteosarcoma in a cow. The nasal tumour. non-painful facial swelling, approximately 14 x 10 cm in diameter, which was situated on the nasal-frontal part of the skull.

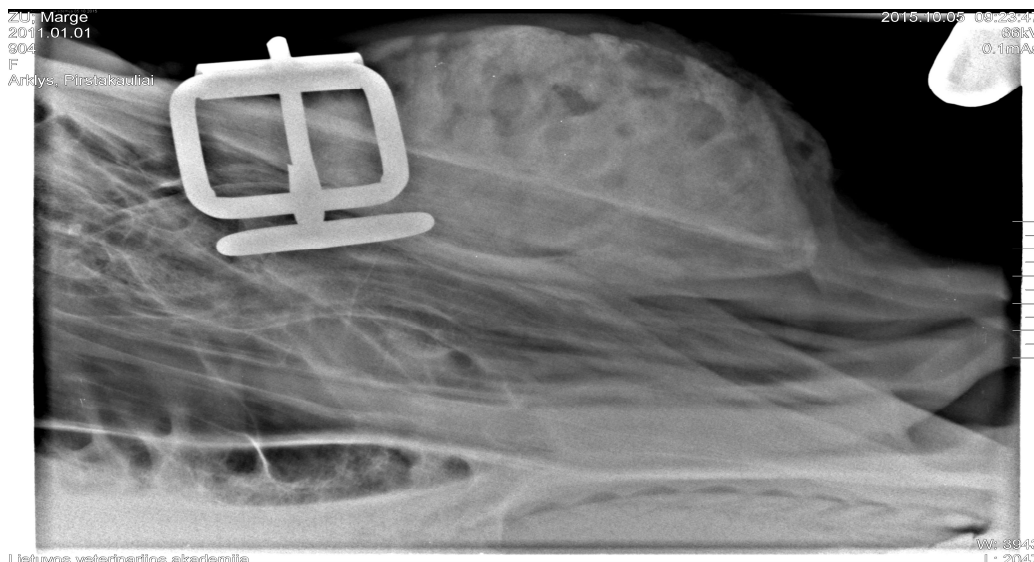


Fig. 2. Osteosarcoma in a cow. Nasal radiograph. Ossification mass.

A clinically healthy cow of similar age and lactation stage was selected for control. After arrival, the cow showed normal appetite and mastication. On clinical examination, the cow had a normal respiratory rate (29 breaths/min.), heart rate (60 beats/min.) and rectal temperature (38,6°C).

A fine-needle aspirate was performed, and sanguineous fluid, consistent with peripheral blood, was obtained. The presumptive diagnosis was a traumatic hematoma, but radiographs of the head revealed mass ossification (Figure 2). Based on the radiographs, primary bone neoplasm was suspected. Osteosarcoma was diagnosed based on the

# International Journal of Innovative Research in Science, Engineering and Technology

(An ISO 3297: 2007 Certified Organization)

Website: [www.ijirset.com](http://www.ijirset.com)

Vol. 6, Issue 2, February 2017

histological evaluation of a biopsy sample. Blood samples for haematology and biochemical analysis were taken every week for three weeks in a row (Table 1).

**Table 1. Blood haematology and biochemical analysis**

	Week 1	Week 2	Week 3	Reference [10]
WBC (T) x10 <sup>9</sup> /L	5.6	5.8	5.27	5.1-13.3
WBC (C) x10 <sup>9</sup> /L	5,5	5,7	5,4	5.1-13.3
LYM (T) x10 <sup>9</sup> /L	2.47	2.39	2.41	1.8-8.1
LYM (C) x10 <sup>9</sup> /L	7,2	6,9	7,1	1.8-8.1
RBC (T) x10 <sup>12</sup> /L	4.27	4.66	4.87	4.9-7.5
RBC (C) x10 <sup>12</sup> /L	5,6	5,5	5,7	4.9-7.5
HGB (T) g/L	69	74	72	84-120
HGB (C) g/L	101	99,8	100	84-120
HCT (T) %	21.69	24.29	24.37	21-30
HCT (C) %	22	23,8	24,8	21-30
MCV (T) fl	51	52	50	36-50
MCV (C) fl	52	51	52	36-50
MCH (T)pg	16.1	15.9	14.7	14-19
MCH (C)pg	16,5	17,3	16,9	14-19
MCHC (T)g/L	317	306	294	380-430
MCHC (C)g/L	320	304	301	380-430
RDWc (T) %	20.6	20.5	20.9	16-20
RDWc (C) %	21,0	20,9	21,1	16-20
PLT (T) x10 <sup>9</sup> /L	394	477	413	160-650
PLT (C) x10 <sup>9</sup> /L	401	450	403	160-650
Calcium (T) mmol/L	2.20	2.20	2.16	2.43-3.10
Calcium, (C) mmol/L	2,5	2,8	2,49	2.43-3.10
Phosphorus (T) mmol/L	3.13	4.44	2.84	3.9-5.8
Phosphorus (C) mmol/L	2,5	2,4	2,2	3.9-5.8
Magnesium (T) mmol/L	0.82	0.84	0.92	0.74-0.95
Magnesium (C) mmol/L	0,83	0,86	0,85	0.74-0.95
Iron (T) mmol/L	10.4	8.9	19.1	10.2-29.0
Iron (C) mmol/L	15,3	12,9	18,9	10.2-29.0
Albumin (T) g/L	25.76	25.04	23.89	30.3-35.5
Albumin (C) g/L	32,3	33,4	32,5	30.3-35.5
AST (T) U/L	59	54	61	78-132
AST (C) U/L	45	56	72	78-132

A. T- test group. C – control group. Table 1. Blood haematology and biochemical finding. No treatment was initiated.

Blood biochemical analysis indicated low calcium, iron and albumin concentrations while the phosphorus concentration was significantly exceeded. Haematology results indicated erythropenia, lymphocytopenia, and a low white blood cell haemoglobin count. Biochemistry results indicated low albumin, calcium and liver enzyme (AST) counts. The clinical presentation, biologic behaviour, histopathology, response-to-treatment, and genetics of OS in dogs are very similar to those in people [2, 9, 10], emphasizing the relevance of dogs as a comparative model. Based upon these unique similarities, dogs that develop OS spontaneously have the capacity to serve as accurate tumour models for deepening our fundamental understanding of OS etiopathogenesis and biology. This review article highlights the commonalities shared between people and dogs with respect to the environmental, bone metabolic and genetic factors that participate in OS etiopathogenesis, and exemplifies how the study of comparative oncology can advance bone

# International Journal of Innovative Research in Science, Engineering and Technology

(An ISO 3297: 2007 Certified Organization)

Website: [www.ijirset.com](http://www.ijirset.com)

Vol. 6, Issue 2, February 2017

sarcoma research. Nasal tumours reported in cattle include osteomas and osteosarcomas of the sinuses, squamous cell carcinomas, neuroblastomas, and adenocarcinomas of the ethmoid mucosa. They tend to occur in cattle 6 to 9 years of age and are frequently unilateral [4].

Taking blood samples is a routine procedure to follow patient condition. Sometimes the total white blood cell count can be virtually unchanged, but decreased lymphocyte counts display osteosarcoma in patients. The tumour is a disease, and it is important to monitor the liver function as indicated by enzyme activity and albumin. The condition of the cow did not worsen during its time in the hospital, as shown in blood tests. A few osteosarcoma cases have been reported in cattle, originating in the maxilla [5, 7], skull [10], nasal cavity [2, 6], abdominal cavity [8] and ischium [10]. Osteosarcoma in humans and small animals is often treated with aggressive surgical procedures, frequently in combination with radiation and/or chemotherapy [3]. In cattle, these techniques are usually impractical because of the location of the tumour and the hazardous consequences regarding food safety. In most cases, any kind of treatment in cattle would not be economically feasible [7].

## III. CONCLUSION

The present case was diagnosed as nasal osteosarcoma, which is rarely reported in cattle. Blood biochemical analysis indicated low calcium, iron and albumin concentrations while the phosphorus concentration was significantly exceeded. Haematology results indicated erythropenia, lymphocytopenia, and a low haemoglobin count.

## REFERENCES

- [1] Bruland, O. S., Hoifodt, H., Saeter, G., Smeland, S. and Fodstad, O., "Hematogenous micrometastases in osteosarcoma patients". Clin. Cancer Res., Vol. 11, pp 4666–4673, 2005.
- [2] Fan, T. M. and Khanna, C., "Comparative Aspects of Osteosarcoma Pathogenesis in Humans and Dogs" Vet. Sci. Vol. 2, pp. 210-230, 2015.
- [3] Makai, F., Belan, A. and Malek, P. "Lymphatic metastases of bone tumors. Lymphology" Vol., 4, pp 109–115, 1971.
- [4] Micheloud, J., F., Guidi, M., G. and Gimeno, E. J., "Osteosarcoma in the skull of a Holstein heifer" Brazilian Journal of Veterinary Pathology, Vol. 8, pp 10-13, 2015.
- [5] Nagamine, E., Matsuda, K., Ishii, C., Koiwa, M. and Taniyama, H. "Primary ischial osteosarcoma occupying the pelvic cavity in a Japanese Black cow". J. Vet. Med. Sci., Vol. 76, pp. 891-894, 2014.
- [6] Plumlee, K. H., Haynes, J. S., Kersting, K. W. and Thompson, J. R., "Osteosarcoma in a cow" J. Am. Vet. Med. Assoc., Vol. 202, pp 95–96, 1993.
- [7] Pospischil, A., Weiland, F., von Sandersleben, J., Hänichen, T. and Schäffler, H. "Endemic ethmoidal tumors in cattle: sarcomas and carcinosarcomas" A light and electron microscopic study. Zentralbl. Veterinarmed. A., Vol. 29, pp 628–636, 1982.
- [8] Smith, B. P. 2009. Large animal internal medicine 4 edition, Mosby Elsevier; 11830 Westline Industrial Drive St. Louis, Missouri, 63146, 592 – 593.
- [9] Withrow, S. J. and MacEwen, E. G., "Clinical veterinary oncology." Philadelphia: J. B. Lippincott, pp. 234–252, 1989.
- [10] Yoshimoto, K., Komagata, M., Chiba, S., Hiro, M., Kobayashi, Y., "A case of nasal osteosarcoma in a Holstein cow" J. Jpn. Vet. Med. Assoc., Vol. 64, pp. 457–460, 2011.