



e-ISSN: 2319-8753 | p-ISSN: 2320-6710

IJIRSET

International Journal of Innovative Research in
SCIENCE | ENGINEERING | TECHNOLOGY

INTERNATIONAL JOURNAL OF INNOVATIVE RESEARCH

IN SCIENCE | ENGINEERING | TECHNOLOGY

Volume 10, Issue 5, May 2021

ISSN INTERNATIONAL
STANDARD
SERIAL
NUMBER
INDIA

Impact Factor: 7.512

9940 572 462

6381 907 438

ijirset@gmail.com

www.ijirset.com

Phenotypic and Genotypic Variations Regarding Earlobe and Hypertrichosis among Human Beings

Dr. Sadhana Kesharwani

Professor, Department of Zoology and Biotechnology, Govt. MH College of Home Science and Science, Jabalpur, MP,
India

ABSTRACT: Hypertrichosis is an excessive growth of hair on a particular area of the body which is abnormal for the age, sex or race of an individual. The presence of the excessive coarse black hair on the auricle of the human ear is referred to as hypertrichosis pinnae auris or hairy ears. The condition is primarily restricted to older men and occasionally observed in females. According to the available literature, hypertrichosis pinnae auris is a Y-linked character. A number of studies have shown that the inheritance of the trait is from father to the son, any exceptions can be attributed to the lack of penetrance of the gene or crossing over from Y to X chromosome. A few researchers have suggested the probability of it being inherited in an autosomal manner. The mode of inheritance of the trait thus, remains controversial as to whether it is Y-linked or autosomal or perhaps both. The present article reviews various available studies on hypertrichosis pinnae auris in different populations of the world. It further deliberates on different aspects of the modes of inheritance of hypertrichosis pinnae auris and discusses the contradictions in its inheritance. The understanding of this area of research is significant for studying morphological variations and their genetic basis, sex differences among individuals and populations together with intergroup differences involving anthropology, anatomy, comparative morphology, personal identification and human genetics. The word 'Hypertrichosis' is derived from 'Hyper' that means over/excess/more than normal and 'trichosis' that refers to any abnormal condition of hair growth.

Thus, hypertrichosis is a condition characterised by the excessive growth of hair and its thickness in a particular area of the body which is not considered normal for the age, sex or ethnicity of an individual [1]. It is the presence of excessive hair on the body parts that otherwise lack hair growing normally. Hairs may be present at a single site or may cover the entire body, with the exception of the palms and soles. This type of hair growth is not confined to androgenic areas or bodily surfaces that depend on androgen for hair growth. Thus, hypertrichosis is considered as an androgen independent growth of hair on the body surface. Hypertrichosis should be differentiated from the term 'HIRUSTISM' which is defined as excess androgen sensitive hair growth. It is often diagnosed in women and children who have hair pattern as that of men. Therefore, hypertrichosis pinnae auris, also known as hairy ears is defined as the presence of the excessive hair growth on the outer helix of the pinna of the human ear. This trait is more commonly observed in older men and intermittent in females, the location of the hairs varying from top of the helix to the lateral side of the helix. Hypertrichosis pinnae auris has been reported in different ethnic groups. In the Online Mendelian Inheritance in Man (OMIM), the molecular catalog of human genes and related disorders, the hypertrichosis pinnae auris is included as hairy ears-139500 or hairy ears, Y-linked-425500 with HEY genetic locus on chromosome Yq.

I. INTRODUCTION

In human, attached earlobes are a dominant feature over free earlobes while hypertrichosis (Y-linked) feature. External human ear is considered to be a highly variable structure showing different morphological and individualistic features in different individuals and population groups. The uniqueness of the ear may be useful in establishing the identity of individuals by direct examination, during the examination of CCTV footage or analysis of the ear prints. Considering the forensic significance of the human ear and ear prints encountered at the scene of the crime, the present study is an attempt to evaluate various morphological characteristics of the ear in a north Indian population. Every human ear is unique and consequently its impression also because of the sufficient variability encountered in the external structure of the ear. The study provides new information on the ear variability and characteristics of a north Indian population which will add to the anthropological knowledge and morphological variability of the ear structure for further use in the forensic examinations particularly in the identification process involving facial and ear images. The researchers are

encouraged to explore possibilities for working on the other populations of the world so that a comparison and conclusion can be established regarding further variability in the structure of the ear in these population groups.

The word ‘Hypertrichosis’ is derived from ‘Hyper’ that means over/ excess/more than normal and ‘trichosis’ that refers to any abnormal condition of hair growth. Thus, hypertrichosis is a condition characterised by the excessive growth of hair and its thickness in a particular area of the body which is not considered normal for the age, sex or ethnicity of an individual [1]. It is the presence of excessive hair on the body parts that otherwise lack hair growing normally. Hairs may be present at a single site or may cover the entire body, with the exception of the palms and soles. This type of hair growth is not confined to androgenic areas or bodily surfaces that depend on androgen for hair growth. Thus, hypertrichosis is considered as an androgen independent growth of hair on the body surface. Hypertrichosis should be differentiated from the term ‘HIRUSTISM’ which is defined as excess androgen sensitive hair growth. It is often diagnosed in women and children who have hair pattern as that of men [2]. Therefore, hypertrichosis pinnae auris, also known as hairy ears is defined as the presence of the excessive hair growth on the outer helix of the pinna of the human ear. This trait is more commonly observed in older men and intermittent in females, the location of the hairs varying from top of the helix to the lateral side of the helix [Fig-1] [3]. Hypertrichosis pinnae auris has been reported in different ethnic groups. In the Online Mendelian Inheritance in Man (OMIM), the molecular catalog of human genes and related disorders, the hypertrichosis pinnae auris is included as hairy ears-139500 or hairy ears, Y-linked-425500 with HEY genetic locus on chromosome Yq [4]. It was classified hypertrichotic diseases into congenital and acquired conditions with generalised versus localised hair growth patterns . [5]. The present review details hypertrichosis pinnae auris, a phenotype characterised by the presence of scanty to marked or bushy growth of hair at the helix or the rim of the ear and near the tragus of the ear .The condition is often considered to be a congenital/acquired form of hypertrichosis. It was referred to the condition as the presence of hairs that are longer, darker and thicker than lanugo (soft, downy and unpigmented foetal hairs) hairs on different areas of the pinna [6]. In some individuals, coarse hairs start appearing on the helix of the ear as the age advances, and it is often referred to as hairy pinna or hairy ears. This condition is observed mostly in men; therefore, is proposed to be a Y-linked chromosomal trait [7-10].

Two mechanisms have been proposed for the development of hypertrichosis [3]. The first mechanism deals with the conversion of the vellus (short, fine and light coloured hair) hair to terminal hairs. The increased production of androgen in adolescence causes the follicles in the axillae, groin, and in males, the beard and chest to grow larger and deeper into the dermis and to be converted into terminal hairs. Thus, the body areas devoid of human hair in hypertrichosis often include switching of vellus hair to terminal hairs. Other mechanism is based on the changes occurring in the hair growth cycle. Hair growth cycle involves three phases: anagen, catagen, and telogen. In the anagen phase (growth phase), the hair grows actively and in the catagen phase (transition phase) the hair follicle shrinks and detaches from the dermal papilla, thereby ceasing the growth of the hair followed by the apoptosis. In the telogen phase (resting phase), hairs begin to shed [3]. The hair follicles possess their own intrinsic growth pattern in the whole body, which may be altered by systemic influences, like androgens, thyroid hormone and growth hormone [10]. Hypertrichosis thus, according to the second mechanism results when the hair follicles remain in anagen phase for longer duration than normal, for their location. The cases which have been reported wherein hypertrichosis results from use of certain drugs/chemical, patients with human immunodeficiency virus infection, infants born to diabetic mothers, in these cases it is often, referred to as the acquired form of hypertrichosis [9].

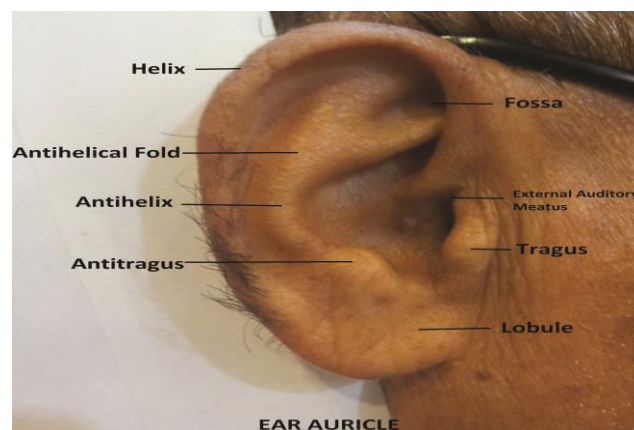


FIG.1- Hypertrichosis pinnae auris, a phenotype characterised by the presence of scanty to marked or bushy growth of hair at the helix or the rim of the ear and near the tragus of the ear

II. DISCUSSION

Many studies in the past reported the inheritance of hairy pinna trait as Y-linked or holandric inheritance. The genes which are present on the differential region of the Y chromosome are commonly referred to as holandric genes. Therefore, the mode of inheritance involving the transmission of such genes from father to son and then to his sons further is called the holandric inheritance. Another characteristic feature of this inheritance is that the females neither transmit the gene nor carry it to the next generation [3].

A work on hairy pinna showed that all the male offspring from the affected male had hairy ears in the pedigree analysed by him [9]. On the other hand none of the female descendants had hairy pinna of the ears, thereby suggesting a linked mode of inheritance for the trait. A scientist [8] after publishing three pedigrees (largest pedigrees consisting seven generation for hypertrichosis inheritance) from Andhra Pradesh interpreted them to be completely Y-linked because of the absence of any evidence for the lack of penetrance and crossing over from Y to X chromosome as hypothesised. [7].

It was examined about 20 pedigrees showing inheritance of the trait from father to son with different degree of hairiness within the same family [7]. The trait was absent in ten offspring of the normal daughters from affected fathers with exception of the two accounting for the lack of penetrance or likely explanation. Sarkar SS et al., studied seven pedigrees from West Bengal and Orissa and found only one pedigree to be compatible with the Y-linkage of hypertrichosis but unable to prove its rightness [5]. The remaining six pedigrees did not fit in the characteristics of holandric inheritance. In none of the pedigrees observed, daughters from affected father had a son with the trait [7]. In another study, examined six pedigrees, which showed Y chromosome inheritance with occasional failure of penetrance [9]. The analysis of the data on Israeli population by some workers stated that the data agree with the hypothesis that this trait is determined by a gene on the Y chromosome [4]. The earliest age of onset of the trait is about 20, but penetrance does not appear to be complete until very late in life.

Though there were assumptions by researchers for the trait to be linked through dominant autosomal inheritance but strong evidence in support of this assumption is required. The existence of genetic heterogeneity remains as such for hypertrichosis pinnae auris.

Noted Exceptions to the Y-linked Inheritance

Sarkar SS et al., reported the deviation from the holandric inheritance in six pedigrees; they were non compatible with the Y-linked inheritance of the trait, as the sons from the affected fathers in second and third generation did not show the trait, thereby presenting contradiction to the above mentioned mode of inheritance [9]. However, in absence of any confirmatory evidences such information necessitated additional conformation [8]. Workers [5] pointed out that it was not examined all the subjects personally and observations in their pedigree was constructed purely on hearsay evidence due to which actual observations may have altered. Subsequently, an exception was observed in a pedigree with the presence of four or five hairs in each ear of the son of an unaffected female [2]. It was noted the occurrence of short, fine black hairs on the ear lobe and lower part of the pinnae in Bengalee female children aged 10-16 years [6]. Also, the father and brother of one of the affected girls exhibited Grade 4 and 2 hypertrichosis respectively. It was reported the dilemma in recording an individual as an affected person because if an affected person is taken as the one who had at least second degree of hairiness then very few individuals are considered to be affected by the trait [7]. Therefore, the assumption that in Y-linkage all the sons from affected fathers are affected appears to be incorrect. Deviation from the Y-linked inheritance assumption was observed by scientists [6]. They suggested the probability of the trait being autosomal dominant sex limited or incompletely sex linked dominantly inherited trait by the observation of hairy ear pinnae among females of south Indian sample in their study.

The Y-linked heritable trait assumption was then investigated in South Indian population [10]. They used 11 Y chromosomal binary markers of 50 unrelated hairy ear males and 50 unrelated unaffected males and found 9 distinct haplogroups in the Y chromosome phylogeny among the affected individuals. They suggested sex limited expression of an autosomal dominant inheritance and hormonal influence for the inheritance of hairy pinna. Their study revealed the non availability of persuasive candidate gene for hypertrichotic phenotypes, thereby, stating the absence of Y linkage for hairs on the ears.

Hairy pinnae can also be considered as an individualising characteristic. The occurrence of hair on the pinnae of the ear could aid in forensic investigations by excluding the criminals in cases of burglary. Sometimes, while listening at the



doors of the target house, the burglars inadvertently leave the prints of their ears [10]; in such a scenario, the patterns of the hair of the hypertrichotic pinnae may be impressed along with the ear prints which might help in narrowing down the search of the culprits. It is also apparent that sensory hair cells present in the cochlea of the ear are responsible for hearing in humans. Thus, in a recent communication, it has been hypothesised that the presence of hairs at the different surfaces of the ear may be associated with the enhancement in the hearing capacity of humans.

III. CONCLUSION

Much of the progress made to understand the inheritance of the hairy pinna of the ear has been through pedigree analysis, but there remains much to be elucidated. Factors such as constitutional ones and ethnicity differences are held responsible for the expression of the gene. New genetic studies have shown molecular evidence for the absence of Y linkage of the hairy ear trait. Future studies should concentrate on poorly understood aspects of its mode of inheritance by identifying the candidate gene responsible for the same, and to find out the underlying mechanism that forms the transmission of the trait from father to offspring as to explore whether single gene or multiple genes are responsible for the hairy ear trait. It has been clearly highlighted in the review that the inheritance pattern of the hypertrichosis pinnae auris is variable in different populations. The understanding of the mode of inheritance of this area of research is significant for studying morphological variations in different population groups, sex differences and intergroup differences and may be useful in many disciplines such as anthropology, human and comparative morphology, personal identification and human genetics. It is further emphasised in the present review that the hypertrichosis pinnae auris has a functional role which may give a future effect for furthering the research in this field.

REFERENCES

- [1]. Garcia-Cruz D, Figuera LE, Cantu JM, Inherited hypertrichosis *Clin Genet* 2002 61:321-29.10.1034/j.1399-0004.2002.610501.x12081714
- [2]. Hohl A, Ronsoni MF, Oliveira MD, Hirsutism: diagnosis and treatment *Arq Bras Endocrinol Metabol* 201458(2):97-107.10.1590/0004-273000000292324830586
- [3]. Wendelin DS, Pope DN, Mallory SB, Hypertrichosis *J Am Acad Dermatol* 2003 48(2):161-79.10.1067/mjd.2003.10012582385
- [4]. Aboud DA, Hairy ears-revisited *Dermatol Online J* 2014 5:215-16.10.7241/ourd.20142.57
- [5]. Olsen EA, Hypertrichosis, In: Olsen EA, Editor *Disorders of hair Growth: Diagnosis and treatment* 1993 NewYorkMcGrawHill:315-36.
- [6]. Basu A, Hairy ears among the Pahira *Acta Genet Med Gemellol* 1965 14:317-25.10.1017/S112096230001369X
- [7]. Gates RR, Y-Chromosome inheritance of hairy ears *Science* 1960 132:145.10.1126/science.132.3420.14513826842
- [8]. Dronamraju KR, Frequencies of hairy pinnae among Indian and Sinhalese peoples *Nature* 1961,190:653.10.1038/190653a013724457
- [9]. Gates RR, Chakravarti MR, Mukherjee DR, Final pedigrees of Y-chromosome *Am J Hum Genet* 1962,14:363-75.
- [10]. Abbie AA, Rao PD, Hairy pinnae in Australian aborigines *Hum Biol* 1965 37:153-55.



INNO  **SPACE**
SJIF Scientific Journal Impact Factor

Impact Factor:
7.512

ISSN INTERNATIONAL
STANDARD
SERIAL
NUMBER
INDIA



INTERNATIONAL JOURNAL OF INNOVATIVE RESEARCH

IN SCIENCE | ENGINEERING | TECHNOLOGY

 **9940 572 462**  **6381 907 438**  **ijirset@gmail.com**



www.ijirset.com

Scan to save the contact details