



e-ISSN: 2319-8753 | p-ISSN: 2347-6710

IJIRSET

International Journal of Innovative Research in
SCIENCE | ENGINEERING | TECHNOLOGY



INTERNATIONAL JOURNAL OF INNOVATIVE RESEARCH

IN SCIENCE | ENGINEERING | TECHNOLOGY

Volume 10, Issue 10, October 2021

ISSN INTERNATIONAL
STANDARD
SERIAL
NUMBER
INDIA

Impact Factor: 7.569



Angio- Lipoma in Anterior Labial Mucosa : A Rare Case Report

Dr. Jyotirmay Chakrawarty¹, Dr. Aashi Fazeela¹, Dr. Ankit Goyal², Dr. Ashish Verma², Dr. Aditee Ingle

Resident Surgical Officer, Dept of Oral and Maxillofacial Surgery, Government Dental College, Indore, M.P. India

Postgraduate trainee, Dept of Oral Pathology and Microbiology, Government Dental College, Indore, M.P. India

Postgraduate trainee, Dept of Oral Pathology and Microbiology, Government Dental College, Indore, M.P. India

Postgraduate trainee, Dept of Oral Pathology and Microbiology, Government Dental College, Indore, M.P. India

Intern, Government Dental College, Indore, M.P. India

ABSTRACT: The lipoma or ubiquitous tumour is a common benign tumour of adipose tissue, but its presence in the oral and maxillofacial region is rare with majority of lipomas occurring in the subcutaneous planes of the neck. Here, we present a case of angiolipoma(a subtype of lipoma) occurring in the anterior labial mucosa of the lower lip and its associated histopathological and surgical management.

KEYWORDS: Lipoma , fatty tumour , adipose , excision , angiolipoma.

I. INTRODUCTION

Lipomas or benign tumours of the adipose(fatty) tissue is the most common mesenchymal tumour present in the oral cavity. Also called as Ubiquitous tumour as it is present everywhere in the human body; it is particularly rare in the oral cavity with a ratio of 1:5000¹. If present in the oral cavity, it most often involves the buccal mucosa, tongue , floor of the mouth , gingiva and is rarely reported to occur in the labial vestibule. Normally seen arising late in the adult life but here, we present a case of intraoral lipoma occurring in the lower labial mucosa and vestibule of a young 20 year old female.

II. CASE REPORT

A 20 year old female reported to the outpatient department of GDC Indore with a chief complaint of painless swelling in the lower anterior labial mucosa since 1 month. The swelling remained of the same size since its onset and was not associated with pain, tenderness , pyrexia or any of the associated symptoms. There were no relevant medical and dental history apart from the fact that the patient underwent minor trauma to the associated area 2 months back.

The extraoral examination(fig1) was not contributory and Intra oral examination reveals round to oval nodule seen in relation to lower labial mucosa(fig2). The nodule appears slight bluish in colour with normal overlying mucosa with no tendency of erythema or ulceration of the lesion as well as surrounding tissues.

Based on the above clinical findings, a provisional diagnosis of Mucocele was made with the differential diagnosis being Intraoral fibroma and intraoral lipoma. To confirm the existing diagnosis, an excisional biopsy was planned as the lesion was small and sent for histopathological examination.

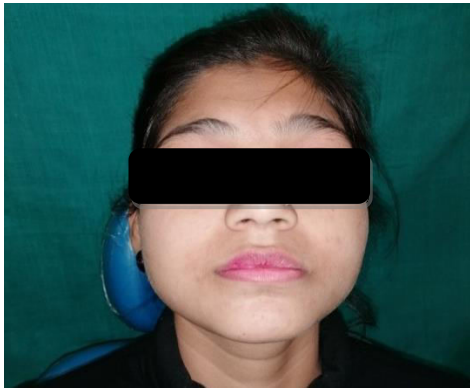

Fig 1: No extraoral findings

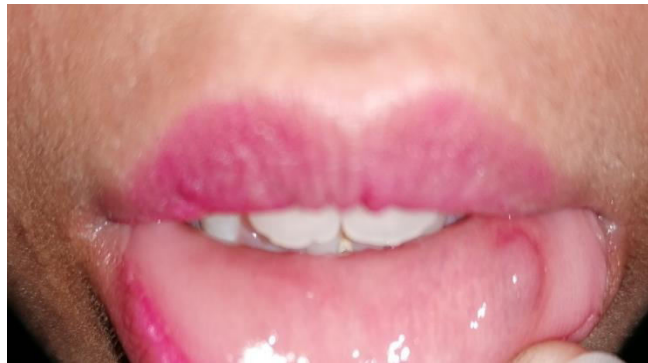


Fig2: Intraoral photograph depicting the lesion

III. HISTOPATHOLOGY

The given H & E stained section revealed (fig 3 and 4) stratified squamous epithelium covering dense connective tissue mass separating lobule of fat cells along with scattered RBC and few blood vessels engorged with RBC and accessory salivary acini. Overall features are suggestive of **Lipoma (Angiolipoma)**.

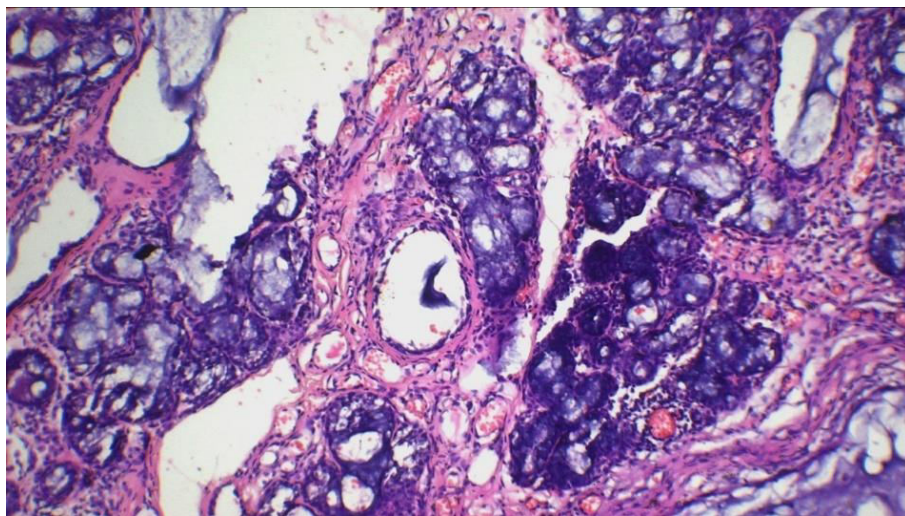


fig 3: 10X view shows dense connective tissue mass separating lobule of fat cells along with scattered RBC and few blood vessels engorged with RBC and accessory salivary acini.

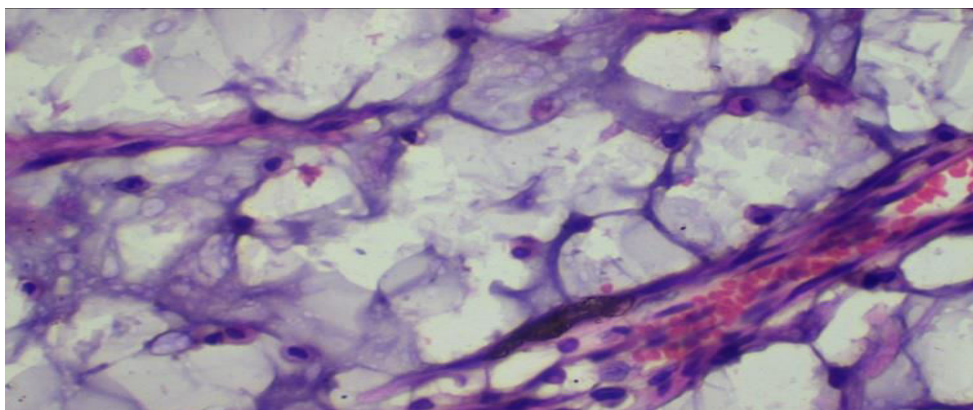


Fig 4: 40X view shows fat cells with peripherally arranged nucleus and few lymphocytes along with extravasated RBC.



IV. DISCUSSION

The lipoma is a very common benign tumour of adipose tissue, but its presence in the oral and maxillofacial region is rare with majority of lipomas occurring in the subcutaneous planes of the neck. The first description of the lesion was first provided by Roux in 1848 in a review of alveolar masses and he referred it to as 'Yellow epulis'¹. Since, then it has been called by a wide variety of names including Lipoma, Ubiquitous tumour, Lipomatosis etc.

Morphologically, the intraoral lipomas can be classified as Diffuse or superficial¹. The superficial lesions appears as single or lobulated, painless lesion attached by either a sessile or a pedunculated base². There is a yellow discolouration, and well encapsulated lipomas are mobile freely beneath the oral mucosa.

On the other hand, deeper lesions produce only a slight elevation of the mucosa, which tends to be more diffuse than the type of the lesion earlier described.⁵

Multiple head and neck lipomas have been associated with von Recklinghausen disease, Proteus syndrome, Gardner syndrome, hemifacial hypertrophy etc.¹

Generally, the lesion is found in adults and has no gender predilection with size less than 3cm at the time of presentation⁵. In our case too, the size was small so that an excisional biopsy was ordered with the specimen being sent to the histopathology department of our college.

Histopathologically, lipomas are composed of mature adipocytes (fat cells), interspersed with collagenic streaks and is often demarcated from the surrounding tissues. A thin fibrous capsule maybe seen and a distant lobular pattern appreciated in the slide. Lipomas can be classified on the basis of histological features as classic lipoma, fibro lipoma, angiolipoma (our present case), spindle cell lipoma, and pleomorphic, myxoid, sialolipoma, and intramuscular lipomas². The treatment of choice for oral lipomas is simple surgical excision. There are only exceptional chances of recurrence. Although the growth of oral lipomas is usually limited, they can reach great dimensions, interfering with speech and mastication and reinforcing the need for excision⁶; In our case, the lesion was small in size without any functional complaint. Still the surgical excision was done because of the patient's concern of an intraoral mass interfering with the movement of the lips.

REFERENCES

1. Rajendran R, Sivapathasundaram B; Shafers Textbook of Oral Pathology, 7th edition, India: Elsevier; 2012.
2. Mohan A, et al. Intraoral Lipoma: Rare Case report with clinical and histopathological study, J Pierre Fauchard Acad (India Sect). (2016)
3. Fregnani ER, Pires FR, Falzoni R, Lopes MA, Vargas PA. Lipomas of the oral cavity: clinical findings, histological classification and proliferative activity of 46 cases. Int J Oral Maxillofac Surg. 2003;32:49–53.
4. Ravi Kiran A, Purnachandrarao Naik N, Samatha Y, J Clin Diagn Res. 2013; 7:3090–3091.
5. Lucas RB. Pathology of Tumors of the Oral Tissues. 4th ed. London, UK: Churchill-Livingstone; 1984:176–179.
6. Kumar LK, Kurien NM, Raghavan VB, et al. Intraoral lipoma: a case report. Case Rep Med. 2014;2014:480130.



**Impact Factor:
7.569**



INTERNATIONAL JOURNAL OF INNOVATIVE RESEARCH

IN SCIENCE | ENGINEERING | TECHNOLOGY

 **9940 572 462**  **6381 907 438**  **ijirset@gmail.com**



www.ijirset.com

Scan to save the contact details