



e-ISSN: 2319-8753 | p-ISSN: 2347-6710

IJIRSET

International Journal of Innovative Research in
SCIENCE | ENGINEERING | TECHNOLOGY



INTERNATIONAL JOURNAL OF INNOVATIVE RESEARCH

IN SCIENCE | ENGINEERING | TECHNOLOGY

Volume 10, Issue 10, October 2021

ISSN INTERNATIONAL
STANDARD
SERIAL
NUMBER
INDIA

Impact Factor: 7.569



An Uncommon Involvement of Pyogenic Granuloma Labiolingually in Mandibular Anterior Region: A Case Report

Dr. Vishal Bamniya¹, Dr. Ajay Pratap Singh Parihar¹, Dr. Jyotirmay Chakrawarty¹,
Dr. Sheetal Singar², Dr. Minali Wadia²

Postgraduate Resident, Dept. of Oral Medicine and Radiology, GDC Indore, India

Professor and HOD, Dept. of Oral Medicine and Radiology, GDC Indore, India

Resident Surgical Officer, Dept. of Oral Surgery, GDC Indore, India

Postgraduate Resident, Dept. of Oral Medicine and Radiology, GDC Indore, India

Intern, GDC Indore, India

ABSTRACT: Pyogenic granuloma is reactive hyperplasia of connective tissue in response to local irritants. It usually arises in response to various stimuli such as low-grade local irritation, traumatic injury, hormonal factors, or certain kinds of drugs. Histologically, the surface epithelium may be intact, show foci of ulceration, or exhibit hyperkeratosis. Treatment ranges from surgical excision with reports of recurrences not uncommon. This paper presents an unusual case of Pyogenic granuloma treated with surgical excision.

KEYWORDS: Pyogenic granuloma, reactive lesion, excision, gingival lesion.

I. INTRODUCTION

Pyogenic granuloma (earlier Granuloma pyogenicum) is a distinctive clinical entity of the tissues occurring in response to non-specific infection. It is thought to be a reactive lesion (tumor-like growth) that is an exaggerated or conditioned response to minor trauma. It is mostly seen in people between 11-40 years of age and has a female predilection and involves the maxillary anterior region and rarely the posterior area.¹

Here, we present a case report of Pyogenic granuloma occurring in a 25-year-old male in the mandibular anterior region involving both the labial and lingual gingiva.

II. CASE REPORT

A 25-year-old male patient reported to the Department of Oral Medicine and Radiology, GDC Indore with a chief complaint of painful swelling in the lower gums for 1 month. The pain was evoked only on provocation of the lesion or on mastication. The swelling increased in size from pea size to the current size with no aggravating or relieving factors. The past medical history was non-contributory although the patient reported trauma to the same area 20 days earlier while using a toothpick.

The extraoral examination (fig1) did not reveal any significant abnormality. Intraoral examination revealed (fig2) an elevated, pedunculated lesion present with respect to the left mandibular anterior region involving both the buccal and lingual gingival with involvement of the interproximal papilla. The mucosa was dark red, smooth with lobulations that showed a tendency to bleed on slight provocation.

Based on the above-mentioned clinical findings, an Orthopantomogram was advised which did not reveal any significant findings. A differential diagnosis of Pyogenic granuloma was made with traumatic fibroma, peripheral ossifying fibroma, papilloma in the differential diagnosis.

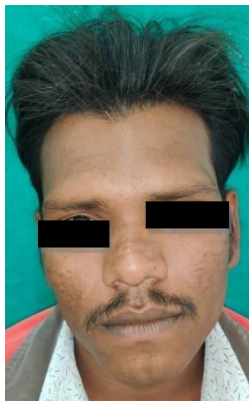

fig 1: Extraoral examination shows no facial asymmetry

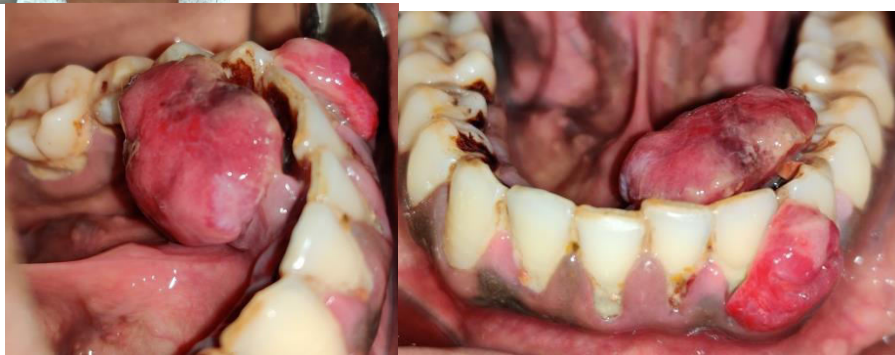

fig 2 and 3: Intraoral examination

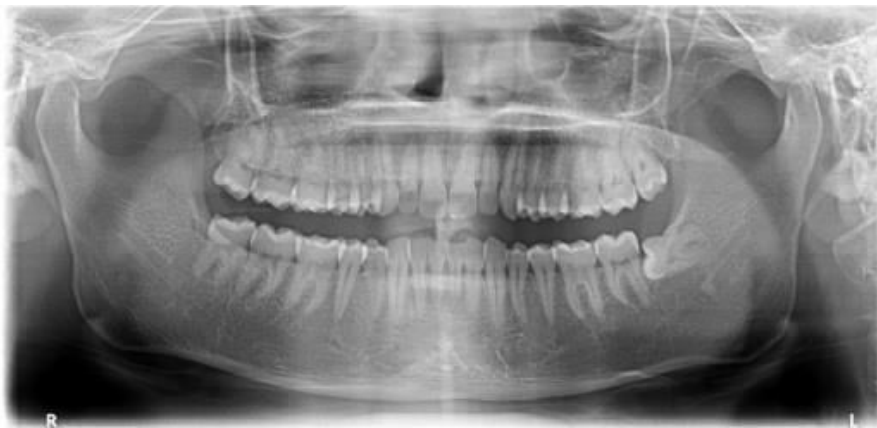

fig 4 : OPG reveals no abnormality

III. SURGICAL TECHNIQUE

A surgical plan of removing the lesion in toto (Excisional biopsy) and exploration of the underlying mucosa was made. As the lesion was pedunculated, the specimen was removed from the stalk with the help of a 15no blade fixed on a 3 no. Bard-Parker handle. The same thing was done on the lingual side as well and the specimen was sent for histopathological examination. After achieving hemostasis and thorough irrigation, the underlying mucosa was checked for any irregularities and a gauze pack was placed on the surgical site to prevent any oo

HISTOPATHOLOGICAL EXAMINATION

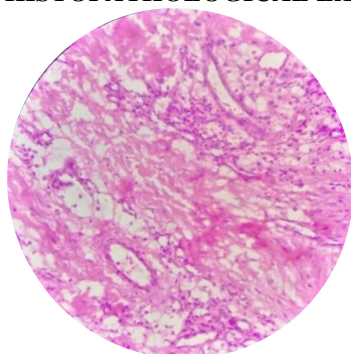


Fig5: The histopathological slide reveals the presence of thin and atrophic epithelium in some areas. The basement membrane appears to be intact.

It overlies a mass of proliferating fibroblasts and a vast majority of endothelium-lined vascular channels and endothelial cells budding. Stroma is richly vascular with numerous small to medium sized, dilated, endothelial cell lined blood vessels showing both intravasated and extravasated RBCs. Dense diffuse chronic inflammatory cell infiltrate chiefly that of lymphocytes are seen. Overall features are suggestive of “Pyogenic Granuloma”

IV. DISCUSSION

Pyogenic granuloma is reactive inflammatory hyperplasia affecting any part of the oral cavity. Hullihen in 1844 described the first pyogenic granuloma reported in the English literature. It was in 1904 that Hartzell introduced the term pyogenic granuloma⁹. It is now agreed universally that this lesion is formed as a result of an exaggerated connective tissue reaction to a minor insult or any underlying irritation¹⁰. The factors contributing to its formation include calculus, poor oral hygiene, nonspecific infection, over-hanging restorations, cheek biting to name a few. This irritation in turn causes the underlying fibrovascular connective tissue to become hyperplastic leading to the proliferation of granulation tissue which leads to the formation of a pyogenic granuloma¹¹.

The pyogenic granuloma may occur at any age but it is mostly seen in the second decade of life in young adult females, possibly because of the vascular effects of female hormones¹¹. The most common site is the gingiva (facial more than lingual or palatal) followed by the buccal mucosa, tongue, and lips⁹. Pyogenic granuloma in general does not have a tendency to reoccur when excised along with its base and all the causative factors are removed or reduced. This paper presents a rare case of pyogenic granuloma occurring in both the labial and lingual surfaces of the mandibular anterior gingiva and its associated surgical management.

Vilman et al, in their study, concluded that the majority of the pyogenic granulomas are found on the marginal gingiva with only 15% of the tumors on the alveolar counterpart⁵. Clinically, these pyogenic granulomas are generally seen as smooth or lobulated exophytic lesions with pedunculated or sessile bases. Pyogenic granuloma differs in size from a few millimeters to several centimeters but rarely do they exceed more than 2.5cm. Various benign soft tissue lesions have to be differentiated from pyogenic granuloma which includes PGCG, Peripheral Ossifying Fibroma, Haemangioma, Pregnancy tumor, Hyperplastic gingival inflammation, or Angiosarcoma. PGCG is often bluish-purple compared to the bright red of typical PG. PGCG is more likely to cause resorption of the bone as compared to Pyogenic granuloma.

Depending on its duration, PG will vary in texture from soft to firm so POF may be another consideration although these will be lighter in color. Also, they are usually less than 1.5cm in diameter which will point to the former diagnosis.¹⁶

Haemangioma is a developmental disorder that has exuberant growth but small lesions may be indistinguishable from Pyogenic granuloma. It can be differentiated with the help of Diascopy, the technique of applying pressure to a vascular lesion to visualize the evacuation of coloration support the fact that potent blood-filled spaces constitute the lesion. Most haemangiomas are located on the tongue where they are multinodular and bluish red and plumper histiocytoid endothelial cell proliferation without inflammatory cell infiltrate is seen in haemangioma.^{17,18}

PG can be differentiated from angiosarcoma by its well defined lobular growth pattern, well-formed vessels, and cytologically bland endothelial cells¹⁹.

Treatment of pyogenic granuloma involves complete surgical excision of the corresponding lesion⁹. Recurrence after surgical debridement is a known complication but can be prevented. The recurrence rate for pyogenic granuloma is said to be 16% of the treated lesions and so re-excision of such lesions might be necessary.



V. CONCLUSION

Pyogenic granuloma is one of the most notorious reactive lesions present in the oral cavity that mimic some dangerous lesions and a thorough history and clinical examination is necessary to accurately make a surgical decision. Although, it has a propensity for recurrence, properly establishing a diagnosis and complete surgical debridement with regular follow-up leads the way for preventing if not eliminating the recurrence and may help the patient for morbidity-free life.

REFERENCES

- [1] Rajendran R, Sivapathasundaram B; Shafers Textbook of Oral Pathology, 7th edition , India: Elsevier;2012.
- [2] Macleod RI, Soames JV. Epulides: a clinicopathological study of a series of 200 consecutive lesions. Br Dent J 1997; 163 : 51-3.
- [3] Anneroth G, Sigurdson A. Hyperplastic lesion of the gingiva and oral mucosa: a study of 175 cases. Acta OdontolScand 1983; 41: 75-86.
- [4] Bhaskar SN, Jacoway JR. Pyogenic granuloma: clinical features, incidence, histology, and result of treatment: report of 242 cases. J Oral Surg 1966; 24(5): 391-8.
- [5] Vilmann A, Vilmann P, Vilmann H. Pyogenic granuloma: evaluation of oral conditions. Br J Oral Maxillofac Surg 1986; 24(5): 376- 82.
- [6] Regezi JA, Sciubba JJ, Jordon RCK. Oral pathology: clinical pathological considerations. 4th ed. Philadelphia, Pa, USA: WB Saunders 2003.
- [7] Mussalli NG, Hopps RM, Johnson NW. Oral pyogenic granuloma as a complication of pregnancy and the use of hormonal contraceptives. Int J GynaecolObstet 1976; 14(2): 187-91.
- [8] Jafarzadeh H, Sanatkhan M, Mohtasham N. Oral pyogenic granuloma: a review. J Oral Sci 2006; 48(4): 167-75.
- [9] Mathur LK, Bhalodi AP, Manohar B, Bhatia A, Rai N, Mathur A. Focal fibrous hyperplasia: a case report. Int J Dent Clin 2010; 2(4): 56-7.
- [10] Kerr DA. Granuloma pyogenicum. Oral Surg Oral Med Oral Pathol 1951; 4(2): 158.
- [11] Lawoyin J, Arotiba J, Dosumu O. Oral pyogenic granuloma: a review of 38 cases from Ibadan, Nigeria. Br J Oral Maxillofac Surg 1997; 35(3): 185-9.
- [12] Zain R, Khoo S, Yeo J. Oral pyogenic granuloma clinical analysis of 304 cases. Singapore Dent J 1995; 20(1): 8-10.
- [13] Miller RAW, Ross JB, Martin J. Multiple granulation tissue lesions occurring in isotretinoin treatment of acne vulgaris: successful response to topical corticosteroid therapy. J Am Acad Dermatol 1985; 12 (5): 888-9.
- [14] Parisi E, Glick P, Glick M. Recurrent intraoral pyogenic granuloma with satellitosis treated with corticosteroids. Oral Dis 2006; 12(1): 70-2.
- [15] Goodman-Topper E, Bimstein E. Pyogenic granuloma as a cause of bone loss in a twelve-year-old child: report of case. ASDC J Dent Child 1994; 61(1): 65-7.
- [16] Bordner L, Dayan (1987) Growth potential of Peripheral Ossifying Fibroma. J Clin Periodontal 14,551-554.
- [17] Enzinger FM, Weiss SW(1995) Soft tissue tumours. 3rded , Mosby, St. Louis, 600
- [18] Calonje E, Wilson-Jones E(1997) Vascular tumours: Tumors and tumor-like conditions of blood vessels and lymphatics in lever's histopathology of the skin, 8th ed, Elder D, Elenitsas R, Jaworsky C, Johnson B Jr Eds, Lippincott-Raven , Philadelphia, 895.
- [19] Pilch BZ(2001) Head and neck surgical pathology. Lippincott Williams and Wilkins, Philadelphia, 389-390



**Impact Factor:
7.569**



INTERNATIONAL JOURNAL OF INNOVATIVE RESEARCH

IN SCIENCE | ENGINEERING | TECHNOLOGY

 **9940 572 462**  **6381 907 438**  **ijirset@gmail.com**



www.ijirset.com

Scan to save the contact details