



e-ISSN: 2319-8753 | p-ISSN: 2347-6710

IJIRSET

International Journal of Innovative Research in
SCIENCE | ENGINEERING | TECHNOLOGY

INTERNATIONAL JOURNAL OF INNOVATIVE RESEARCH

IN SCIENCE | ENGINEERING | TECHNOLOGY

Volume 12, Issue 11, November 2023

ISSN INTERNATIONAL
STANDARD
SERIAL
NUMBER
INDIA

Impact Factor: 8.423

9940 572 462

6381 907 438

ijirset@gmail.com

www.ijirset.com

CSR Detection Using OCT Images

Mitali Bedmutha¹, Utkarsh Bhutada², Nikita Dhule³, Yash Walunjkar⁴

Department of Computer Engineering, Trinity Academy of Engineering, Pune, India¹⁻⁴

ABSTRACT: The visual restructuring of items in the environment is the function of the human eye. The retina, which is in charge of absorbing light and producing electrical impulses for further processing in the brain, is the most significant component of the eye. The eye is separated into various layers and front and back regions. Numerous manual and automated strategies have been proposed to diagnose retinal illnesses; however, patients find these methods to be inconvenient, time-consuming, and inefficient.

The clotting of fluids underneath the retinal surface causes Central Serous Retinopathy (CSR), often referred to as Central Serous Chorioretinopathy (CSC). The retina is made up of tiny tissues that absorb light and allow the brain to recognize images. This important and vital organ may become injured, leading to the people's loss of eyesight and eventual blindness. As a result, early diagnosis of the disease may prevent total blindness and, in certain situations, allow vision to return to normal. Therefore, early and precise identification of CSR prevents serious damage to the macula and serves as a foundation for the identification of other retinal diseases.

CSR has been identified using Optical Coherence Tomographic (OCT) pictures, but developing a system that is both accurate and computationally economical is still a difficult task. Using deep convolutional neural networks that have already been trained, this study creates a framework for the precise and automatic identification of CSR from OCT images. The OCT image preprocessing improves and filters the images to reduce noise and improve contrast, respectively..

KEYWORDS: Central Serous Retinopathy (CSR), Optical Coherence Tomography (OCT) images, Machine Learning, Deep Learning, Data Augmentation

I. INTRODUCTION

1.1 Anatomy of Human Eye

Human vision is provided by the eye, an organ that is sensitive to light. Human eyes are made up of the subsequent sections: Iris, the colored portion of the eye that regulates the amount of cornea, the transparent layer in front of the eye that helps with light entry. The pupil, which is the round, blackish aperture that lets light in when focusing, conjunctive: a thin layer of tissue covering the front of the eye, excluding the cornea and lens focuses the light on the eye's retina. Nonetheless, the majority of the eyeball is filled with a colorless substance known as vitreous.

Additionally, the retina is a lining on the back of the eye made up of light-sensing cells. Cone, rod, and other photoreceptive cells in the retina are able to detect light rays, and they use the optic nerves to send this information to the brain. Central vision is attributed to the macula, a small region located in the center of the retina. Rays of light from the object being viewed enter the vitreous and focus on the retina.

When an object is illuminated, light beams from it enter the vitreous and concentrate on the retina. Subsequently, the light signals are transformed into impulses by the retinal cells and transmitted through millions of optic nerve neurons. Because of the cornea's irregular shape, light rays are bent at different angles, which occasionally results in blurry images. The cornea's other roles include initiating the refractive process and shielding the eye from outside debris. Since the cornea is an essential component of the eye, even small damage can result in vision loss.

Common visual disorders include macular degeneration, which results in central vision loss as people age, cataracts, or clouding of the lens, which cause blurry vision, glaucoma, which is caused by increased intraocular pressure and long-term visual impairment, optic neuritis, which is caused by inflammation of the optic nerve due to various conditions like immune response, retinitis, or inflammation of the retina, and central serous retinopathy (CSR), which is caused by fibrin deposits in the macula.

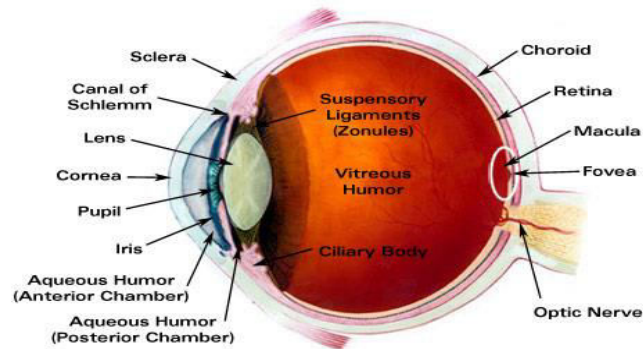


Fig 1. Human Eye Anatomy

1.2 Central Serous Retinopathy

The macula, which is the middle region of your retina, is impacted by central serous retinopathy (CSR) or central serous chorioretinopathy (CSCR). The light-sensitive tissue located in the back of your eye is called the retina. Your vision may become distorted and blurry as a result of CSR because fluid may accumulate under your macula. One eye is typically affected by the illness.

CSR primarily affects individuals in the 20–50 age range, with a higher prevalence in men than in women. But it can also happen to elderly people. For the majority of people, CSR improves on its own and has no long-term effects on vision. It might, however, come back for some people. Long-lasting or recurring episodes of CSR are more likely to result in long-term changes to your vision.

There are multiple layers in your retina, and they have to cooperate in order for you to see. The choroid is a layer of tissue behind the retina that is densely packed with blood vessels. Under the retina, the RPE functions as a pump and barrier to prevent fluid accumulation from the choroid.

If the RPE does not function properly, CSR arises. The central macula area swells when choroid fluid passes through the RPE and begins to accumulate beneath your retina. Because it allows you to see color and fine detail when looking directly at objects, like books, faces, or television screens, the macula's health is extremely important. As a result, your macula provides your central vision, and the remaining portion of your retina provides your peripheral (side) vision.

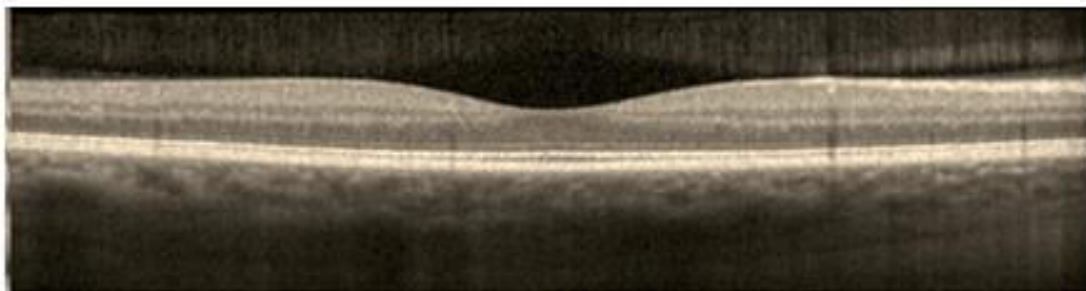


Fig 1.2 Normal Eye flat macula

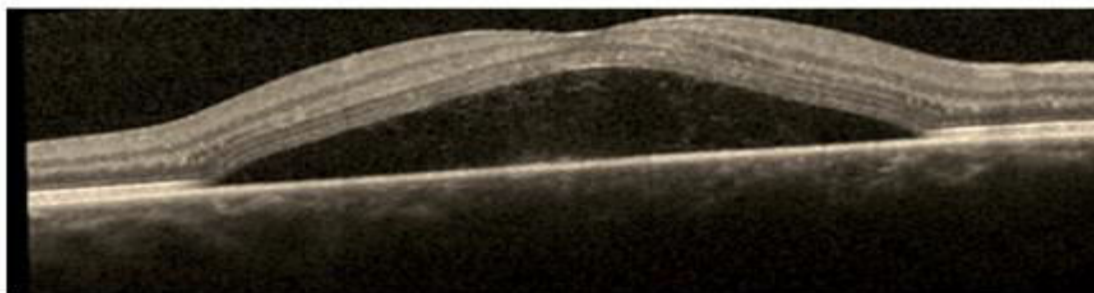


Fig 1.3 Eye with fluid underneath the macula (CSR)



II. LITERATURE REVIEW

Number	Paper Name	Author Name and Year	Proposed System	Referred Point
1.	“Recent Developments in Detection of Central Serous Retinopathy through Imaging and Artificial Intelligence Techniques,” IEEE Access journal	Syed Ale Hassan, Shahzad Akbar, Amjad Rehman. 2021	This paper presents recent advancements in the detection of Central Serous Retinopathy using imaging and Artificial Intelligence techniques.	Improve central serous retinopathy detection capabilities and make detection systems applicable to an even broader range of applications using emerging Artificial Intelligence techniques.
2.	"Retinal imaging analysis based on vessel detection"	A. Jamal, M. Hazim Alkawaz M, A. Rehman, T. Saba. 2017	In this paper, we explored retinal imaging analysis of eye and effects of csr.	The effects of central serous retinopathy on humans and causes.
3.	“Deep learning-based automatic detection of central serous retinopathy on optical coherence tomographic (OCT) images” Published in 1st Int. Conf. Artificial Intelligence Data Analytics (CAIDA).	S. A. E. Hassan, S. Akbar, S. Gull, A. Rehman, and H. Alaska. 2021	In this paper, based on The most recognized use of artificial intelligence (AI) strategies in retinal disease are the development of spots intricate to disease characteristics on color fundus photos. In this context, programmed segmentation and characterization of anatomic and pathologic have been combined and applied in retinal diseases	Use of artificial intelligence techniques in recognizing retinal disease.
4.	“A Survey on Computer Algorithms for Retinal image Preprocessing and Vessel Segmentation,” 2020 International Conference on Inventive Computation Technologies (ICICT)	M. Vijaya Maheswari; G. Murugeswari. 2020	In this paper, we conducted a survey on computer algorithms for retinal image preprocessing and vessel segmentation	Explored various computer algorithms for retinal images preprocessing and make system to broader range.



5.	“Automated diagnosis of macular edema and central serous retinopathy through robust re-construction of 3D retinal surfaces”	A. M. Syed, T. Hassan, M. U. Akram, S. Naz, and S. Khalid. 2016	In this paper, we presented automated diagnosis of macular edema and Central Serous Retinopathy through the robust reconstruction of 3D retinal surfaces	Improve reconstruction of 3D retinal surfaces for diagnosis of central serous retinopathy and issues related with macula.
6.	“A comprehensive review on various preprocessing methods in detecting diabetic retinopathy” 2019 International Conference on Communication and Signal Processing (ICCSP)	B. Ramasubramanian, S. Selvaperumal, A. Nasim, and A. Jameel. 2019	In this paper, we conducted a comprehensive review of various preprocessing methods for detecting diabetic retinopathy	The insights into the surveyed preprocessing methods, and potential directions for future research in the field of diabetic retinopathy detection
7.	”Detection of choroidal neovascularization in central serous chorioretinopathy using optical coherence tomographic images.”	S. Weng, L. Mao, S. Yu, Y. Gong, L. Cheng, and X. Chen. 2016	In this paper, published research on the identification of choroidal neovascularization in central serous chorioretinopathy using optical coherence tomographic angiography	The significance of the study's results, and potential avenues for future research in the identification of CSR using OCT Image.
8.	“Automatic detection of central serous chorioretinopathy and central exudative chorioretinopathy in fundus images.	Wen Y, Chen L, Qiao L, Deng Y, Dai S, Chen J, Zhou C. 2020	In this paper, presented their work on the automatic detection of central serous chorioretinopathy and central exudative chorioretinopathy in fundus images	Accuracy improvements are achieved by the automatic detection of central serous chorioretinopathy .
9.	“Tracing of Central serous retinopathy from retinal fundus images.”	David J, Kumar AS, Viji V. 2009	In this paper, we discussed the tracking of central serous retinopathy from retinal fundus images	Implications of the tracking method for understanding and managing CSR. Suggestions for future research in the field of CSR tracking from retinal fundus images.

10.	"Deep learningbased automatic detection of central serous retinopathy using optical coherence tomographic images."	Hassan SAE, Akbar S, Gull S, Rehman A, Alaska H. 2021	We presented their collaboration with In-depth study using optical coherence switchboard tomography images to detect serous retinopathy	Presentation of results related to the detection of serous retinopathy using OCT images. Evaluation metrics or visual representations demonstrating the study outcomes.
-----	--	---	---	---

III. DESIGN METHODOLOGY

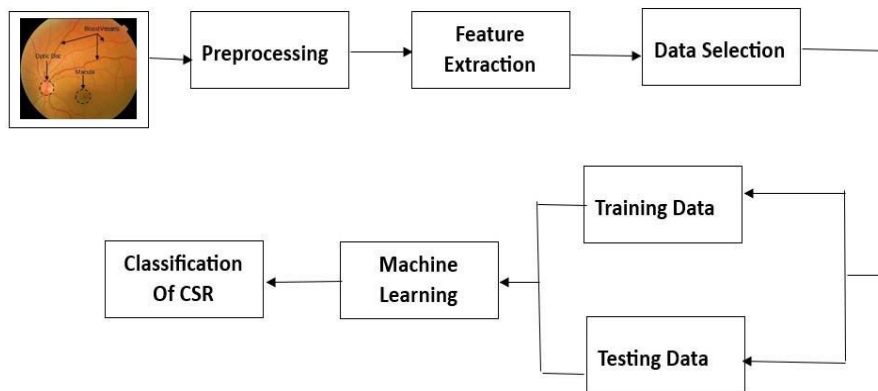


Fig. ML Model

Machine Learning (ML) is further categorized into supervised, unsupervised and reinforcement learning. In case of supervised learning, the targeted variables are predicted from a prearranged indicator (known as the Objective Function) for simplicity. Taking advantage of arrangement of factors, generation of the Objective Function guides contribution to anticipated targets. The dataset training phase keeps iterating until the model attains an ideal degree of precision. The examples of supervised learning techniques are Regression & Logistic Regression, KNN, Decision Tree, and Random Forest, etc. In unsupervised learning, the prediction of the objective or desired variable is carried out. It is employed for the collecting population in various groups, which is broadly used for fragmenting purposes. It is programmed to strategically learn itself when introduced to a certain circumstance and up- skill reliably with trial and error experimentation. This allows the algorithm to experience and attempt to catch the ideal data to attain the precise business choices. An example of reinforcement learning includes Markov Decision Process.

The process starts with inputting a retinal image, which is preprocessed for any anomaly detection or better visualization for the next stages. After preprocessing, the next stage is feature extraction in which various parts and features of the eye scan are extracted. Then specific parts of the scan are selected for training or testing purposes. If the image is inputted specifically for the training purpose, it is processed through various algorithmic stages to boost up the ML model, thereby obtaining a particular pre-classified CSR related image. Contrarily, if the image was initially inputted for testing purposes, then it goes through the predefined algorithmic stage to test the model for its validation. In this way, the model is first trained using a large dataset of images, and then tested using more data. Once the algorithmic model goes through hundreds of thousands of images, it is trained determine any CSR diseases in future inputted images. Deep Learning (DL) is an advanced version of ML based on neural networks capable of unsupervised learning from an unstructured and unlabeled dataset. In recent studies, DL algorithms are vastly used by researchers and scientists in almost every field including image recognition and automated disease detection. In ophthalmology, DL has been applied to fundus images, optical intelligibility tomography and visual fields, accomplishing robust classification execution in the discovery of CSR.

IV. CONCLUSION

The detection of Central Serous Retinopathy (CSR) has witnessed significant progress through the utilization of Optical Coherence Tomography (OCT) imaging. This non-invasive technology has evolved to offer high-resolution images, enabling more precise visualization and characterization of CSR lesions in CSR patients. Furthermore, the integration of artificial intelligence (AI) and machine learning algorithms has streamlined CSR detection and segmentation within OCT images, enhancing diagnostic accuracy. The combination of OCT with other imaging modalities, such as fluorescein angiography, has improved the ability to distinguish CSR subtypes and provide more accurate diagnoses. The growing adoption of telemedicine and remote monitoring has allowed for early CSR detection and facilitated timely interventions. OCT is also invaluable for monitoring treatment responses, guiding personalized medicine approaches, and supporting clinical research. Collaborative efforts between medical professionals and engineers have led to advancements in OCT technology for CSR management, with a focus on obtaining regulatory approvals for OCT-based diagnostic tools. Patient education regarding the role of OCT in diagnosis and monitoring is becoming increasingly important, empowering individuals to actively participate in managing their condition and understanding treatment options. It's crucial to stay updated with the evolving landscape of medical imaging and CSR detection using OCT through ongoing research

REFERENCES

1. Syed Ale Hassan, Shahzad Akbar, Amjad Rehman, "Recent Developments in Detection of Central Serous Retinopathy through Imaging and Artificial Intelligence Techniques," IEEE Access journal, 2021
2. A. Jamal, M. Hazim Alkawaz M, A. Rehman, T. Saba "Retinal imaging analysis based on vessel detection". Microsc Res Tech. vol. 80, no. 17,799-811, 2017.
3. S. A. E. Hassan, S. Akbar, S. Gull, A. Rehman, and H. Alaska. "Deep learning-based automatic detection of central serous retinopathy on optical coherence tomographic (OCT) images" Published in 1st Int. Conf. Artificial Intelligence Data Analytics (CAIDA), Apr. 2021
4. M. Vijaya Maheswari; G. Murugeswari, "A Survey on Computer Algorithms for Retinal image Preprocessing and Vessel Segmentation," 2020 International Conference on Inventive Computation Technologies (ICICT), Date of Conference: 26-28 February 2020, DOI 10.1109/ICICT48043.2020.9112470.
5. M. Syed, T. Hassan, M. U. Akram, S. Naz, and S. Khalid, "Automated diagnosis of macular edema and central serous retinopathy through robust re- construction of 3D retinal surfaces,' Comput. Methods Programs Biomed., vol. 137, pp. 1–10, Dec. 2016, doi: 10.1016/j.cmpb.2016.09.004.
6. Ramasubramanian, S. Selvaperumal, A. Nasim, and A. Jameel, "A comprehensive review on various preprocessing methods in detecting diabetic retinopathy" 2019 International Conference on Communication and Signal Processing (ICCSP), Date of Conference: 06-08 April 2019.
7. S. Weng, L. Mao, S. Yu, Y. Gong, L. Cheng, and X. Chen, "Detection of choroidal neovascularization in central serous chorioretinopathy using optical coherence tomographic angiography," Ophthalmologica vol. 236, no. 2, pp.114-121, 2016.
8. Wen Y, Chen L, Qiao L, Deng Y, Dai S, Chen J, Zhou C (2020) On automatic detection of central serous chorioretinopathy and central exudative chorioretinopathy in fundus images. In 2020 IEEE International Conference on Bioinformatics and Biomedicine (BIBM). Seoul, Korea (South), (pp 1161–1165).
9. David J, Kumar AS, Viji V (2009) Tracing of Central serous retinopathy from retinal fundus images. In 13th International Conference on Biomedical Engineering. Singapore, (pp 331–334).
10. Hassan SAE, Akbar S, Gull S, Rehman A, Alaska H (2021) Deep learning based automatic detection of central serous retinopathy using optical coherence tomographic images. In 2021 1st International Conference on Artificial Intelligence and Data Analytics (CAIDA). Riyadh, Saudia Arabia, (pp 206–211)



INNO SPACE
SJIF Scientific Journal Impact Factor
Impact Factor: 8.423



ISSN INTERNATIONAL
STANDARD
SERIAL
NUMBER
INDIA



INTERNATIONAL JOURNAL OF INNOVATIVE RESEARCH

IN SCIENCE | ENGINEERING | TECHNOLOGY

 **9940 572 462**  **6381 907 438**  **ijirset@gmail.com**



www.ijirset.com

Scan to save the contact details